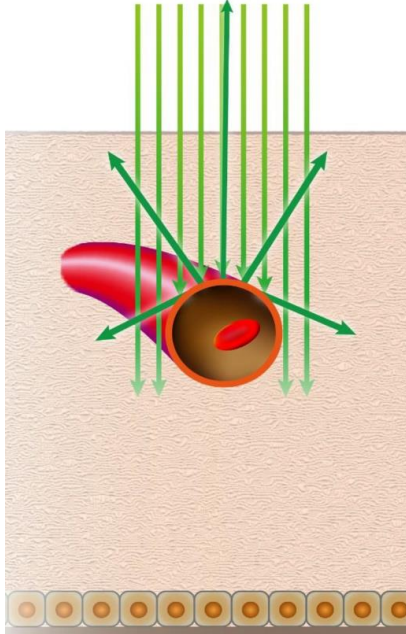


Supplemental figure3: Schematic image of higher green intensity of retinal arterial sclerosis in color SLO image.



Color SLO showed a stronger green tint in the retinal arterioles of patients with higher CAVI. The green tone of the retinal artery becomes stronger at the thickening arterial wall in the eye with higher CAVI.