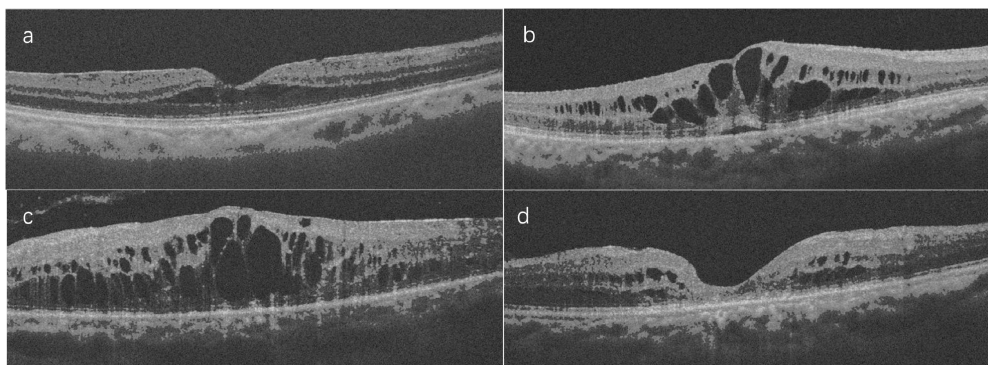


## Supplemental figure



Representative enhanced optical coherence tomography images: a. early diabetic macular edema (DME). b. advanced DME. c. severe DME. d. atrophic maculopathy.

Supplemental table AUC and F1 score of our model in validation dataset		
DM stages	AUC	F1 score (%)
Early DME	0.9607	87.74
Advanced DME	0.9542	84.06
Severe DME	0.8703	88.18
Atrophic maculopathy	0.9770	88.57

DM: diabetic maculopathy; DME: diabetic macular edema; AUC: area under the receiver operating characteristic curve