

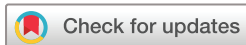Primary and additional treatment preference in aggressive retinopathy of prematurity and type 1 retinopathy of prematurity

Ji Hye Jang ,¹ Yong Koo Kang,² Han Sang Park,² Kiyoung Kim,³ Sung Soo Kim,⁴ Jae Yong Han,⁴ Hyun Wong Kim,⁵ Jong Wook Bang,⁵ Jae Shin Song,⁶ Sang Jun Park ,⁶ Se Joon Woo ,⁶ Kwang Sic Joo,⁶ Woong-Sun Yoo,⁷ Inyoung Chung,⁷ Yong-Wun Cho,⁷ Jong Hyun Lee,⁸ Hun Jin Choi,⁸ Yoo-Ri Chung ⁹

To cite: Jang JH, Kang YK, Park HS, *et al.* Primary and additional treatment preference in aggressive retinopathy of prematurity and type 1 retinopathy of prematurity. *BMJ Open Ophthalmology* 2023;**8**:e001166. doi:10.1136/bmjophth-2022-001166

▶ Additional supplemental material is published online only. To view, please visit the journal online (<http://dx.doi.org/10.1136/bmjophth-2022-001166>).

Received 15 September 2022
Accepted 12 January 2023



© Author(s) (or their employer(s)) 2023. Re-use permitted under CC BY-NC. No commercial re-use. See rights and permissions. Published by BMJ.

For numbered affiliations see end of article.

Correspondence to

Dr Ji Hye Jang; mjmom99@naver.com

ABSTRACT

Objective This study aimed to evaluate the preference for anti-vascular endothelial growth factor (anti-VEGF) versus laser ablation therapy as primary and additional treatment in aggressive retinopathy of prematurity (ROP) and type 1 ROP.

Methods This multicentre retrospective study was conducted at nine medical centres across South Korea. A total of 94 preterm infants with ROP who underwent primary treatment between January 2020 and December 2021 were enrolled. All eyes were classified as having type 1 ROP or aggressive ROP. Data on the zone, primary treatment chosen, injection dose, presence of reactivation and additional treatment were collected and analysed.

Results Seventy infants (131 eyes) with type 1 ROP and 24 infants (45 eyes) with aggressive ROP were included. Anti-VEGF injection was selected as the primary treatment in 74.05% of the infants with type 1 ROP and 88.89% with aggressive ROP. Anti-VEGF injection was selected as the ROP was located in zone I or posterior zone II, and laser ablation was selected when it was located in zone II. The anti-VEGF injection doses varied and tended to be higher in the aggressive ROP group. Infants with aggressive ROP were 2.08 times more likely to require additional treatment than those with type 1 ROP. When ROP reactivation occurred, laser therapy was preferred as an additional treatment.

Conclusion In Korea, the preference for anti-VEGF therapy or laser therapy differed according to ROP subtype, zone and primary or secondary treatment. These findings suggest that ROP treatment are considered according to ROP subtype, location and reactivation.

INTRODUCTION

Retinopathy of prematurity (ROP) is a disease that occurs in preterm infants due to the abnormal development of retinal blood vessels, in which neovascular proliferation occurs at the junction of the vascular-avascular retina or within the vascularised retina, progressing to tractional retinal

WHAT IS ALREADY KNOWN ON THIS TOPIC

⇒ Current treatments for aggressive retinopathy of prematurity (ROP) and type 1 ROP include intravitreal anti-vascular endothelial growth factor (anti-VEGF) injection or laser ablation.

WHAT THIS STUDY ADDS

⇒ Anti-VEGF agents were chosen as the primary treatment when the ROP zone was located in the central region, and laser ablation was selected when the zone was located in the peripheral retina. Anti-VEGF injections were preferred for aggressive ROP over type 1 ROP, and higher doses were used in aggressive ROP. If additional treatment was required, laser ablation was selected as a secondary treatment.

HOW THIS STUDY MIGHT AFFECT RESEARCH, PRACTICE OR POLICY

⇒ These findings suggest that ROP treatment are considered according to ROP subtype, location and reactivation.

detachment.^{1 2} This is one of the leading causes of low vision and vision loss in children and can be prevented if treated promptly.³

Innovations in retinal imaging have changed the concepts of ROP zone, stage and plus disease.⁴⁻⁶ The International Classification of ROP, Third Edition (ICROP3),⁷ defines the term *the posterior zone II* as an area of two disc diameters between zone I and zone II, describes a continuous spectrum of vascular changes from normal to plus disease and recommends the use of the term *aggressive ROP* instead of *aggressive posterior ROP*. Therefore, it is necessary to study whether the new classification of ROP cases based on the ICROP3 differs from the existing ROP classification in terms of disease progression and treatment effects.



Recently, anti-vascular endothelial growth factor (anti-VEGF) agents have emerged as a promising alternative to laser therapy for the treatment of ROP. The Bevacizumab Eliminate the Angiogenic Treat (BEAT)-ROP study⁸ reported that intravitreal bevacizumab (Avastin, Genentech Inc, San Francisco, California, USA) injection was more effective than laser ablation for zone I stage 3+ROP. In addition, the RAINBOW trial⁹ showed that infants treated with ranibizumab 0.2 mg (Lucentis, Genentech Inc) had superior efficacy compared with laser therapy. Therefore, the use of anti-VEGF agents for ROP treatment is expected to increase rapidly. However, studies on the extent and dose of bevacizumab or ranibizumab in real clinical practice are lacking.

Incomplete regression and reactivation of ROP after anti-VEGF treatment have become important issues to note after the acute phase of ROP.^{10,11} It is not clear which treatment is actually selected by a retinal specialist when ROP is reactivated. Therefore, treatment guidelines for ROP reactivation after intravitreal anti-VEGF injections are required.

Therefore, we aimed to investigate the treatment options and short-term outcomes in aggressive ROP and type 1 ROP, including the actual doses of anti-VEGF agents and the additional treatment tendencies with recurrence or incomplete regression.

MATERIALS AND METHODS

This was a retrospective multicentre study in which members of the Korean Retina Society participated. Details about the purpose of the study, inclusion and exclusion criteria were communicated to members who expressed an interest in participating in the study, and data were collected via a case report form (CRF) for analysis.

From 1 January 2020 to 31 December 2021, preterm infants with gestational age (GA) less than 37 weeks were examined. Infants who died before the follow-up examination and those who were transferred to another hospital were excluded. Diagnosis and classification of ROP were performed by expert retinal specialists at each hospital according to the ICROP3.⁷

Preterm infants with ROP who required treatment were enrolled in this study (online supplemental figure 1). All eyes with treatment-requiring ROP were classified as type 1 ROP or aggressive ROP. If both eyes received different treatments, then each eye of the infant was included separately in each treatment group. Demographic data, such as sex, GA at birth and birth weight (BW), were collected from the medical records. Ophthalmological data including postmenstrual age (PMA) at every examination, ROP subtype at diagnosis, primary treatment choice, duration of plus disease disappearance after primary treatment, retinal state at every examination, need for additional treatment, secondary treatment choice and local or systemic complications were collected via CRF. Furthermore, the locations of treatment-requiring ROP at diagnosis were divided into zones I,

posterior zone II and zone II. For treatment, it was investigated which of the following three treatments would be used as the primary treatment: intravitreal anti-VEGF injection therapy, laser ablation therapy or combination (anti-VEGF injection is administered with laser ablation in the same day) therapy. If intravitreal injection therapy was chosen, the anti-VEGF agents and injection dosages were recorded.

Cases with insufficient treatment or recurrent ROP were further analysed. Insufficient treatment was defined as a case in which the lesion did not completely disappear and the plus disease persisted even after the first treatment within 4 weeks. Reactivation was defined as the reappearance of plus disease or the recurrence of lesions above the ridge stage at the advancing edge after 4 weeks. When additional treatment was administered, the trends in selecting secondary treatment options for additional treatment, the selected anti-VEGF injection agent and dose were investigated. Treatment failure was considered if it progressed to tractional retinal detachment and required surgery, if the ROP was so severe that ophthalmological examination was not possible or if further treatment was discontinued. Furthermore, during the follow-up period, monitoring was conducted to determine if there were any adverse reactions or events following additional treatment.

The demographic data of this study were collected and analysed by the participants. Ophthalmological data were collected and analysed by eye, not by subject. Continuous variable data, such as GA, BW, PMA and duration, were expressed as mean±SD. Discrete variables were expressed as numbers and percentages. IBM SPSS Statistics (V.25.0; IBM Corp, Armonk, New York, USA) was used to statistically analyse the collected data, and statistical significance was set at $p<0.05$.

RESULTS

Characteristics depending on the treatment-requiring ROP subtype

A total of 176 eyes of 94 infants (12 eyes in unilateral cases) received primary treatment; only these eyes were included in this study. In six eyes (three infants), both eyes received the same treatment on different days. In six eyes (three infants), each eye received different treatments and were included in each treatment subgroup. Table 1 shows the demographic and clinical characteristics of the infants with type 1 ROP or aggressive ROP.

The mean GA for type 1 ROP was 25.7±1.8 weeks, while the mean GA for aggressive ROP was 25.2±2.0 weeks. The mean BW for type 1 ROP was 832.01±274.84 g, whereas it was 824.21±311.87 g for aggressive ROP, indicating no statistical significance between the two groups. The location of type 1 ROP at primary treatment was 18:34:79 for zone I: posterior zone II: zone II, whereas the location of aggressive ROP was 20:6:19, indicating that lesions occurred more frequently in the zone I area in aggressive ROP than in type 1 ROP (44.25% vs 13.74%, $p<0.0001$). The mean values of PMA at primary treatment were

Table 1 The demographic and clinical characteristics of the infants with type 1 ROP or aggressive ROP

Parameters	Infants with type 1 ROP (n=70, 131 eyes)	Infants with aggressive ROP (n=24, 45 eyes)	P value
Gestational age, weeks	25.7±1.8	25.2±2.0	0.2311
Birth weight, g	832.01±274.84	824.21±311.87	0.9079
ROP zone at primary treatment, eyes			
Zone I	18 eyes	20 eyes	<0.0001*
Posterior zone II	34 eyes	6 eyes	
Zone II	79 eyes	19 eyes	
PMA at primary treatment, weeks	38.3±6.1	35.6±3.4	0.0003*
Primary treatment choice, eyes			
Anti-VEGF injection monotherapy	97 eyes	40 eyes	0.1075
Laser ablation monotherapy	32 eyes	5 eyes	
Combination (anti-VEGF+laser treatment)	2 eyes	none	
Time of plus disease disappearance after primary treatment, days	17.9±16.3 ~ not disappear	28.7±14.1 ~ not disappear	0.0467*
Additional treatment-requiring eyes	35 eyes (26.72%)	25 eyes (55.56%)	0.0004*
Values of gestational age, birth weight, PMA at primary treatment and periods of plus disease disappearance in each group are presented as mean±SD.			
*Statistically significant by the Pearson's χ^2 test or Fisher's exact test.			
anti-VEGF, anti-vascular endothelial growth factor. PMA, postmenstrual age; ROP, retinopathy of prematurity;			

38.3±6.1 weeks in type I ROP and 35.6±3.4 weeks in aggressive ROP, indicating significantly different between groups. In the type I ROP group, intravitreal anti-VEGF injection was administered as the primary treatment in 97 eyes (74.05%), laser ablation in 32 eyes (24.42%) and combination therapy in two eyes (1.53%). In the aggressive ROP group, anti-VEGF drugs in 40 eyes (88.89%) and laser ablations in five eyes (11.11%) were selected as the primary treatment. After primary treatment, the mean duration of plus disease disappearance was 17.9±16.3 days for type 1 ROP (two eyes, did not disappear plus disease until retreatment was decided) and 28.7±14.1 days for aggressive ROP (four eyes, did not disappear), indicating significant differences between groups. Thirty-five eyes (26.72%) with type 1 ROP and 25 eyes (55.56%) with aggressive ROP required additional treatment after initial treatment, which was 2.08 times higher than that of type 1 ROP.

Primary treatment choice and response to treatment in type 1 ROP

Type 1 ROP was diagnosed in 131 eyes of 70 preterm infants. Anti-VEGF injections were administered to 97 eyes (intravitreal bevacizumab injections in 37 eyes and intravitreal ranibizumab injections in 60 eyes), laser therapy in 32 eyes and combination therapy in two eyes as the primary treatment (table 2).

In the type 1 ROP bevacizumab-treated subgroup (n=39 eyes), the ROP zone at primary treatment was zone I in six eyes, posterior zone II in 10 eyes and zone II in 21 eyes. The injection dosage of bevacizumab was 0.625 mg/0.025 mL in 12 eyes (half of the adult dose for

treatments of macular oedema and age-related macular degeneration), 0.5 mg in 12 eyes, 0.375 mg in 6 eyes and 0.2 mg in 10 eyes. It took 11.6±8.4 days after injections for plus disease to completely disappear. During follow-up examination, reactivation of ROP was observed in 10 eyes, and the mean periods from primary treatment to secondary treatment was 38.6±9.8 days. In all cases of reactivated ROP, laser therapy was performed as a secondary treatment, and there was no progression to retinal detachment.

In the type 1 ROP ranibizumab-treated subgroup (n=60 eyes), the zone of type 1 ROP was located in zone I in 10 eyes, posterior zone II in 21 eyes and zone II in 29 eyes. The injection dosage was 0.2 mg/0.02 mL (the same dose as performed in the RAINBOW study) in 48 eyes and 0.1 mg in 12 eyes. It took 14.7±14.5 days for plus disease to completely disappear after injection, but plus disease did not disappear in two eyes, until retreatment was performed. Additional treatment-requiring ROP occurred in 25 eyes, and their mean time to retreatment was 71.8±38.0 days.

Laser therapy was performed as the primary treatment for 32 eyes. At the time of treatment, the zone of type 1 ROP was located in zone I in 2 eyes, posterior zone II in 3 eyes and zone II in 27 eyes. After laser treatment, it took 34.1±26.2 days for the plus disease to completely disappear, and there were no cases that required additional treatment.

Combination therapy was performed in two eyes of two infants. In two cases, coadministration of anti-VEGF agent was 0.5 mg and 0.25 mg of bevacizumab, respectively,

Table 2 Primary treatment choice and response to treatment in type 1 retinopathy of prematurity (ROP)

Parameter	Bevacizumab injection (37 eyes)	Ranibizumab injection (60 eyes)	Laser ablation (32 eyes)	Combination therapy (2 eyes)
ROP zone at primary treatment, eyes				
Zone I	6 eyes	10 eyes	2 eyes	None
Posterior zone II	10 eyes	21 eyes	3 eyes	None
Zone II	21 eyes	29 eyes	27 eyes	2 eyes
PMA at primary treatment, weeks	38.4±4.2	36.3±2.8	43.5±14.1	37.5
Anti-VEGF injection dose and numbers				
	B 0.625 mg 9 eyes	R 0.2 mg 48 eyes	none	B 0.5 mg 1 eye
	B 0.5 mg 12 eyes	R 0.1 mg 12 eyes	none	B 0.25 mg 1 eye
	B 0.325 mg 6 eyes		none	
	B 0.2 mg 10 eyes		none	
Periods of plus disease disappearance after primary treatment, days	11.6±8.4	14.7±14.5 ~ not disappear	34.1±26.2	14
Additional treatment-requiring eyes	10 eyes (27.03%)	25 eyes (41.67%)	None	None
Duration of additional treatment after primary treatment, days	38.6±9.8	71.8±38.0	–	–
Values of gestational age, birth weight, PMA at primary treatment, periods of plus disease disappearance and duration of additional treatment in each subgroup are presented as mean±SD.				
anti-VEGF, anti-vascular endothelial growth factor; B, bevacizumab; PMA, postmenstrual age; R, ranibizumab;				

and no secondary treatment was required during the follow-up period.

Primary treatment choice and response to treatment in aggressive ROP

Among the 45 eyes of 24 preterm infants with aggressive ROP, 40 eyes (7 eyes of bevacizumab, 33 eyes of ranibizumab)

selected anti-VEGF injection and five eyes selected laser treatment as their primary treatment (table 3).

In the aggressive ROP bevacizumab-treated subgroup (n=7), the ROP zone at the first treatment was zone 1 in one eye, zone 2 in two eyes and zone 2 in four eyes. The injection dosage of bevacizumab was 0.625 mg

Table 3 Primary treatment choice and response to treatment in aggressive retinopathy of prematurity (ROP)

Parameter	Bevacizumab injection (7 eyes)	Ranibizumab injection (33 eyes)	Laser ablation (5 eyes)
ROP zone at primary treatment			
Zone I	1 eyes	19 eyes	none
Posterior zone II	2 eyes	4 eyes	none
Zone II	4 eyes	10 eyes	5 eyes
PMA at primary treatment, weeks	36.3±2.7	36.3±2.8	39.2±5.9
Anti-VEGF injection dose and numbers			
	B 0.625 mg 5 eyes	R 0.25 mg 9 eyes	none
	B 0.5 mg 2 eyes	R 0.2 mg 16 eyes	
		R 0.1 mg 8 eyes	
Periods of plus disease disappearance after primary treatment, days	47.6±12.7	22.1±25.8 ~ not disappear	20.2±11.3
Additional treatment-requiring eyes	2 eyes (28.58%)	21 eyes (63.64%)	2 eyes (40.00%)
Duration of additional treatment after primary treatment, days	18	62.3±40.9	13
Values of gestational age, birth weight, PMA at primary treatment, periods of plus disease disappearance and duration of additional treatment each subgroup are presented as mean±SD.			
anti-VEGF, anti-vascular endothelial growth factor; B, bevacizumab; PMA, postmenstrual age; R, ranibizumab.			

in five eyes and 0.5 mg in two eyes. It took an average time of 47.6 ± 12.7 days for plus disease to disappear after bevacizumab treatment. Both eyes receiving 0.5 mg of bevacizumab had insufficient regression within 4 weeks and required further treatment.

In the aggressive ROP ranibizumab-treated subgroup ($n=33$), ROP lesion were located in zone I in 19 eyes, posterior zone II in 4 eyes and zone II in 10 eyes; the injection dosage for treatment was 0.25 mg for 9 eyes, 0.2 mg for 16 eyes and 0.1 mg for 8 eyes. In 29 eyes, plus disease disappeared after the first injections, which took 22.1 ± 25.8 days on average. However, it did not completely disappear in four eyes; therefore, additional treatment was required. Additional treatment was performed for 21 eyes, including three eyes because of a lack of treatment and 18 eyes because of reactivation. The mean interval time between primary treatment and additional treatment was 62.3 ± 40.9 days. During the follow-up period, none of the patients progressed to retinal detachment.

Laser therapy was primarily performed in five eyes, and the lesions were located in zone II in all eyes. In three eyes, plus disease disappeared after primary treatment, which took 20.2 ± 11.3 days. However, because plus disease in two eyes did not disappear within 4 weeks, it was regarded as a lack of treatment, and secondary treatment was performed. During the follow-up period, none of the patients progressed to retinal detachment.

Additional treatment due to reactivation and lack of treatment

In 34.09% of all cases, additional treatment was required because of insufficient treatment and ROP reactivation after the primary treatment. In type 1 ROP, additional treatment was performed in 35 eyes (26.72%) out of 131 eyes (figure 1). In the bevacizumab-treatment subgroup of type 1 ROP, 10 out of 37 eyes received secondary treatment. Reactivation occurred in two eyes injected with 0.625 mg bevacizumab, four eyes injected with 0.5 mg bevacizumab and four eyes injected with 0.325 mg bevacizumab during primary treatment. Reactivation occurred in two eyes (2/6, 33.3%) with an initial ROP located in zone I, four eyes (4/10, 40.0%) in posterior zone II and two eyes (2/21, 9.5%) in zone II. Laser therapy was additionally performed as a secondary treatment for all eyes, and no further treatment was required. In the type 1 ROP ranibizumab-treatment subgroup, 25 out of 60 eyes received additional treatment, and all of them received ranibizumab 0.2 mg injection as the primary treatment. Regarding the ROP zone at primary treatment, additional treatment was done 7 eyes (7/10, 70.0%) in zone I, 8 eyes (8/21, 38.1%) in posterior zone II, 10 eyes (10/29, 34.5%) in zone II. Two eyes were treated with laser ablation due to a lack of treatment. In addition, 23 eyes were treated as a result of ROP reactivation, among which 19 received laser therapy and 5 received ranibizumab 0.2 mg injections. In one eye, where ranibizumab was injected twice consecutively, the therapeutic effect was

Baseline (primary treatment days) in Type 1 ROP

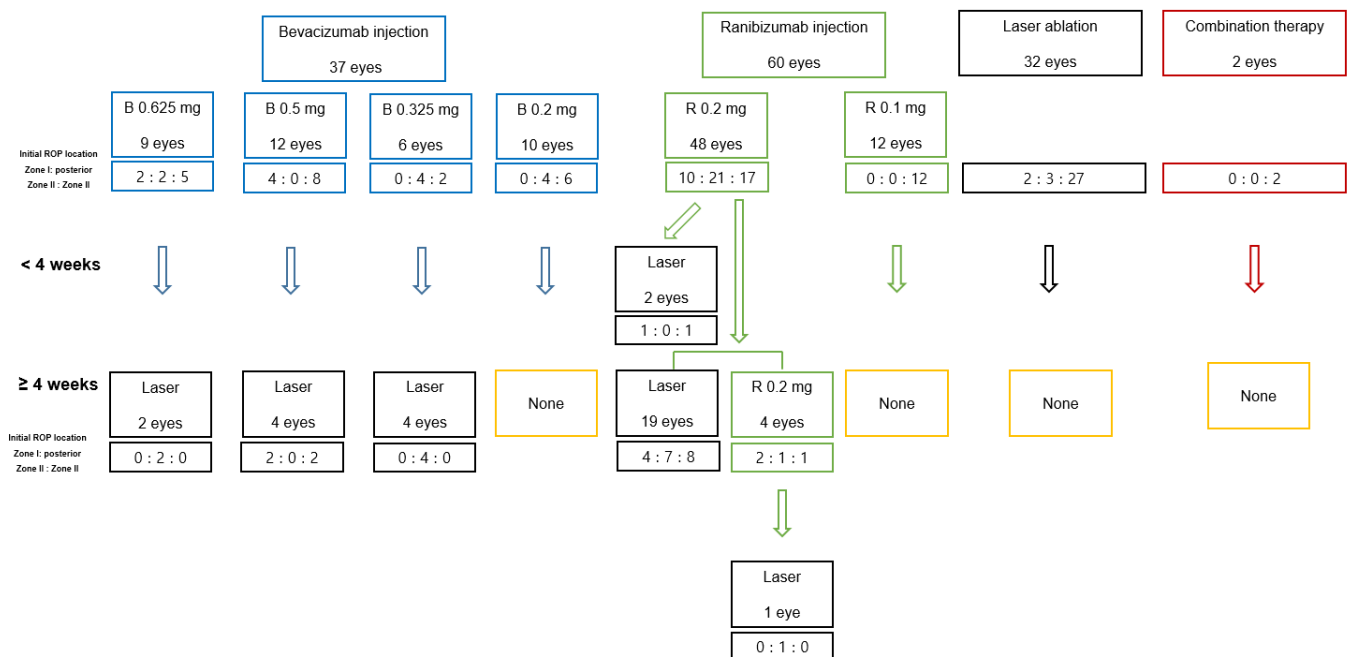


Figure 1 Additional treatment choice trends in cases of reactivation or lack of primary treatment in type 1 retinopathy of prematurity (ROP). The flow chart shows the number of eyes that received at least one additional treatment. Additional treatment was performed within 4 weeks of the primary treatment because of a lack of treatment. If ROP was reactivated, it was performed 4 weeks after the primary treatment. The initial ROP zone was divided into zone I: posterior zone II: zone II, and the corresponding cases (eyes) was indicated with a number. B, bevacizumab; R, ranibizumab.

Baseline (primary treatment days) in aggressive ROP

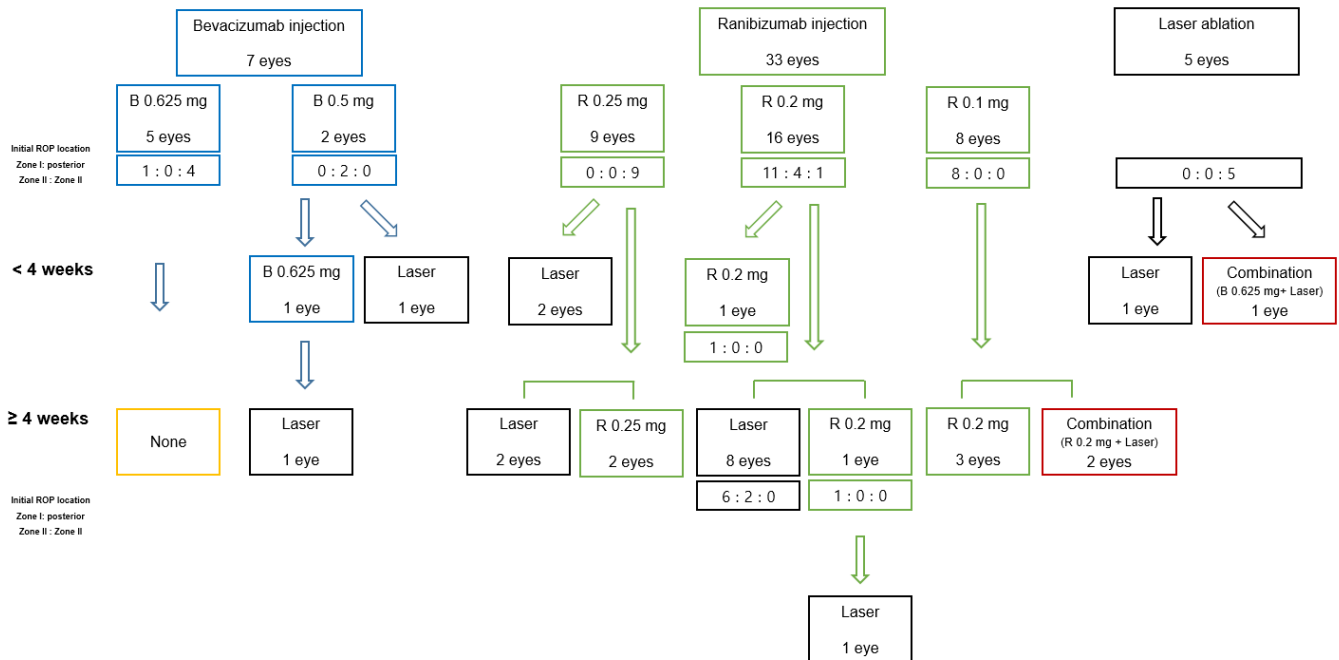


Figure 2 Additional treatment choice trends in cases of reactivation or lack of primary treatment in aggressive retinopathy of prematurity (ROP). The flow chart shows the number of eyes that received at least one additional treatment. Additional treatment was performed within 4 weeks of the primary treatment because of a lack of treatment. If ROP was reactivated, it was performed 4 weeks after the primary treatment. The initial ROP zone was divided into zone I: posterior zone II: zone II, and the corresponding cases (eyes) was indicated with a number. B, bevacizumab; R, ranibizumab.

insufficient; therefore, laser treatment was additionally performed 93 days after the second treatment. Reactivation did not occur in the laser therapy or combination therapy groups; therefore, secondary treatment was not required.

Secondary treatment was performed in 25 (55.56%) out of 45 eyes with aggressive ROP, and none of the eyes progressed to retinal detachment during the follow-up period (figure 2). In the aggressive ROP bevacizumab-treatment subgroup, only two eyes injected with bevacizumab 0.5 mg as the primary treatment received additional treatment due to lack of treatment. One eye that received laser treatment as secondary treatment no longer required additional treatment. In the other eye, where the plus disease did not disappear even 1 week after the first injection, 0.625 mg of bevacizumab was injected as an additional treatment. However, there was no improvement after the second injection, and the laser treatment was administered 23 days later.

In the aggressive ROP ranibizumab-treatment subgroup, additional treatment was performed for 21 eyes, which included 6 out of 9 eyes with 0.25 mg of ranibizumab injected, 10 out of 16 eyes with 0.2 mg injected and 5 out of 8 eyes with 0.1 mg injected during primary treatment. Additional treatment was performed in 13 eyes (13/19, 68.4%) in zone I, two eyes (2/4, 50.0%) in posterior zone II, six eyes (6/9, 66.7%) in zone II. Owing to insufficient treatment, three eyes received secondary

treatment, among which two eyes received laser therapy and one eye received anti-VEGF injection treatment consecutively. Secondary treatment was performed in 18 eyes with recurrent ROP. Laser treatment was performed in 10 eyes, ranibizumab injection in six eyes and combination therapy in two eyes. In all cases in which the second injection of ranibizumab was administered, the same or higher dose than the first injection was selected. Among the two consecutive injections of ranibizumab, one eye did not regress; therefore, laser ablation was performed as the third treatment. In the laser therapy group, secondary treatment was performed in two out of five eyes due to insufficient treatment. At that time, one eye received additional laser treatment and the other eye was treated in combination with bevacizumab 0.625 mg.

DISCUSSION

Based on multicentre clinical data, this study was divided into type 1 ROP and aggressive ROP, investigated the tendency to select anti-VEGF injections and laser ablation as the primary treatment in real clinical settings, the injection dose and frequency and the need for additional treatment after primary treatment.

The study findings are summarised as follows: (1) when selecting primary treatment, retinal specialists selected anti-VEGF injections when the ROP zone was located closer to the central area, whereas they selected laser therapy when lesions were located in the peripheral

area, indicating a preference for anti-VEGF injections for aggressive ROP rather than type 1 ROP; (2) the dose of anti-VEGF injections administered by retinal specialists varied, and a higher dose was injected into the vitreous cavity in aggressive ROP than in type 1 ROP; (3) 34.09% of the eyes receiving primary treatment received additional treatment due to the lack of treatment and reactivation of ROP, which occurred more frequently with anti-VEGF injection than with laser treatment, and more frequently required additional treatment, especially in aggressive ROP; (4) if additional treatment was required, laser therapy was preferentially selected. However, if an anti-VEGF injection was selected, it was administered at a dose equal to or greater than the primary injection dose.

The key to treating type 1 ROP and aggressive ROP is to reduce the amount of VEGF in the retina and vitreous cavity.¹ Current treatment are laser ablation, which burns the avascular retina to reduce the number of retinal cells that produce VEGF,¹² and intravitreal anti-VEGF injections that reduce VEGF levels by binding between VEGF and the anti-VEGF agents in the eye.^{13–14} Intravitreal anti-VEGF injections in use include bevacizumab (off-label use),⁸ ranibizumab (EU approved drug)⁹ and aflibercept (off-label use; a phase III study is being conducted on this).^{15–16} Intravitreal injection therapy is becoming increasingly popular because it is simpler to perform and provides a faster treatment response than conventional laser therapy.^{17–18}

The rate of disease progression in infants with ROP requiring treatment varies depending on the subtypes (type 1 ROP vs aggressive ROP) and location of lesions (zone I vs posterior zone II or zone II),^{19–20} so the effects of laser therapy and intravitreal injections may differ. Çömez *et al*²¹ reported that although intravitreal anti-VEGF injections were effective for aggressive ROP and type 1 ROP with zone I and posterior zone II lesion, additional treatment was required in many cases of aggressive ROP. Roohipoor *et al*²² reported that both laser therapy and anti-VEGF injection treatment were effective for type 1 ROP with zone II, but retreatment was lower with laser therapy.

In this study, Korean retinal specialists showed a tendency to choose anti-VEGF injection when ROP was located in zone I or posterior zone II and to select laser treatment when ROP was located in zone II. It has also been shown that anti-VEGF treatment is more frequently selected for aggressive ROP than for type 1 ROP. The reason is as follows: aggressive ROP is characterised by marked plus disease, no noticeable findings at the junction of vascular and avascular retina and a rapid progression of vascular abnormalities.^{21–23–24} Because the tempo of aggressive ROP is fast, anti-VEGF injection is more effective than laser therapy in lowering the high concentration of VEGF in the eye rapidly. Laser therapy has the advantage of reducing reactivation by destroying the avascular retina,²⁵ but the wider the laser treatment area, the narrower the field of view. In particular, in the case of aggressive ROP, it

may be difficult to determine the laser treatment range because the boundary between the avascular retina and vascular retina is not prominent.²³ In addition, since PMA at the primary treatment for aggressive ROP is earlier than that for type 1 ROP, it seems that anti-VEGF injection therapy is preferable to laser therapy because premature infants have poor lung function and cannot tolerate general anaesthesia.

The appropriate injection dose and frequency of intravitreal anti-VEGF injections are controversial because of the risks of ocular and systemic exposure. The dose of bevacizumab administered in the BEAT-ROP study⁸ was 0.625 mg, which is half the adult dose. The RAINBOW study⁹ used ranibizumab 0.2 mg (equivalent to 40% of the clinically approved adult dose for age-related macular degeneration) and ranibizumab 0.1 mg. When it considers that the vitreous capacity of premature infants is approximately 1/4 that of adults, it can be considered a high dose.¹ In age-related macular degeneration, the intravitreal half-life of bevacizumab was approximately 4.9–6.7 days, and its serum half-life was measured to be 11.3–18.7 days,²⁶ while in ROP, the serum half-life of bevacizumab was 21 days on average, and serum bevacizumab was detected for more than 2 months.^{27–28} In the case of neovascular macular degeneration, the intravitreal half-life of ranibizumab was 9 days and its serum half-life was 2 hours.²⁹ In ROP, the intravitreal half-life of ranibizumab was as short as 5.6 days, and the serum half-life was 7.2 hours (0.3 days), which took longer than the case of macular degeneration.³⁰ As a result, premature infants have a longer serum half-life of anti-VEGF agents than adults, so it takes longer for the VEGF concentration to return to normal. Since bevacizumab has an Fc domain, it takes time to remove, and its serum half-life is much longer than that of ranibizumab by about 20 days, which increases the risk of systemic exposure.³¹ When using anti-VEGF injections for the treatment of ROP, it is recommended to use a small dose of bevacizumab or a drug with a short serum half-life, such as ranibizumab.^{32–33} However, other aggressive ROP studies^{34–36} have used ranibizumab doses of 0.25–0.3 mg. Similarly, our study showed that although the dose of VEGF administered by retinal specialists varied, they tended to select higher doses for aggressive ROP than for type 1 ROP. Therefore, further studies are needed to determine the appropriate injection dose according to the subtype and lesion of ROP.

Reactivation of ROP usually occurs after anti-VEGF injection and rarely after laser treatment, with complete regression or incomplete regression of the original lesion.⁷ Reactivation phase proceeds in various ways from the demarcation line to the stage requiring treatment. However, reactivation is defined differently in the literature,³⁷ and the degree of reactivation has been reported differently depending on the types and doses of therapeutic agents as well as the study period.^{38–39} In our study, treatment insufficiency and reactivation were classified based on 4 weeks before and after the first treatment.

Currently, there is no clear consensus on when and how to treat reactivation. Martínez-Castellanos *et al*⁴⁰ proposed a treatment algorithm for treatment failure and reactivation of ROP after bevacizumab injection. They recommended that anti-VEGF injection should be repeated if new lesions above the ridge stage reappear or flat new blood vessels are observed at the advanced edge, and vitrectomy should be performed if vitreous traction is observed on the ridge lesion.

In this study, 52 eyes received secondary treatment for ROP reactivation, and no vitrectomy was performed in any case. Secondary treatment was required more frequently with anti-VEGF injections than with laser therapy, as well as more frequently with ranibizumab than with bevacizumab. It should be noted that the duration of additional treatment after primary treatment was shorter with bevacizumab than with ranibizumab. The reason is that although there are few cases, in the case of bevacizumab, laser ablation was performed if it was determined that additional treatment was needed within 2–6 weeks. There were no cases where the injection agent was administered more than three times, and there were no cases where another anti-VEGF agent was selected for reinjection. In all cases of the second injection, a higher dose than the first injection or the same dose as the first injection was selected. If the therapeutic effect was judged to be insufficient after two consecutive injections, laser treatment was performed. Based on our experience, laser treatment should be preferred if additional treatment is required, and it is not necessary to select a dose lower than the primary treatment when selecting anti-VEGF.

The limitation of this study include that the members of the Korean Retinopathy Society who participated in the study were informed of the standardised classification of ROP and plus disease, but the classification and treatment selection of ROP was based on individual judgement. In addition, the types and doses of anti-VEGF injections used in the study varied, and long-term follow-up and safety studies were lacking. Additional studies are needed more effective doses and frequencies of intravitreal anti-VEGF injections for ROP. However, this study presents data on the preference of anti-VEGF injection therapy as a primary treatment and as an additional treatment in a real clinical setting for ROP requiring treatment over the last 2 years. This is expected to be of great help to retinal specialists interested in anti-VEGF injections for ROP treatment.

In conclusion, this study is noteworthy in that it confirms the tendency to select intravitreal anti-VEGF injections or laser ablation according to the subtype of ROP and location of the lesion. It may also be helpful to come up with new guidelines for ROP treatment by understanding the tendency to opt for second-line treatment when reactivation occurs after injection. These findings suggest that ROP treatments are considered according to ROP subtype, location and reactivation in actual clinic situation.

Author affiliations

¹Department of Ophthalmology, Dongsan Medical Center, Keimyung University School of Medicine, Daegu, Korea (the Republic of)

²Department of Ophthalmology, Kyungpook National University School of Medicine, Daegu, Korea (the Republic of)

³Department of Ophthalmology, Kyung Hee University School of Medicine, Seoul, Korea (the Republic of)

⁴The Institute of Vision Research, Department of Ophthalmology, Severance Hospital, Yonsei University College of Medicine, Seodaemun-gu, Korea (the Republic of)

⁵Department of Ophthalmology, Haeundae Paik Hospital, Inje University College of Medicine, Busan, Korea (the Republic of)

⁶Department of Ophthalmology, Seoul National University Bundang Hospital, Seoul National University College of Medicine, Seoul, Korea (the Republic of)

⁷Department of Ophthalmology, Gyeongsang National University School of Medicine, Jinju, Korea (the Republic of)

⁸Department of Ophthalmology, Ilsan Paik Hospital, Inje University College of Medicine, Busan, Korea (the Republic of)

⁹Department of Ophthalmology, Ajou University School of Medicine, Suwon, Korea (the Republic of)

Acknowledgements The authors would like to thank the members of the Korean Retinal Society for their interest and participation in this study.

Contributors JJH has full access to the data and takes overall responsibility. Conception and design: JJH. Data collection: all authors. Writing of the manuscript: JJH. Guarantor, JJH.

Funding This study was supported by a research grant from The Korean Retina Society in 2020, and the National Research Foundation of Korea grant funded by the Korean government (Ministry of Science and ICT) (No. 2022R1G1A1011107).

Patient and public involvement Patients and/or the public were involved in the design, or conduct, or reporting, or dissemination plans of this research. Refer to the Methods section for further details.

Patient consent for publication Not applicable.

Ethics approval This multicentre study was approved by the Institutional Review Board of participating hospitals: Keimyung University Dongsan Medical Center (DSMC 2021-08-076), Kyungpook National Hospital (KNUH 2022-02-021-002), Kyung Hee University Hospital (KHUH 2022-06-022), Yonsei University Severance Hospital (4-2022-0263), Inje University University Haeundae Paik Hospital (HPIRB 2022-07-026), Seoul National University Bundang Hospital (B-21111-720-303), Gyeongsang National University Hospital (GNUB 2022-06-016), Inje University University Ilsan Paik Hospital (ISPAIK 2022-03-023-001) and Ajou University School of Medicine (AJIRB-MED-20-508). Participants gave informed consent to participate in the study before taking part.

Provenance and peer review Not commissioned; externally peer reviewed.

Data availability statement Data are available on reasonable request.

Supplemental material This content has been supplied by the author(s). It has not been vetted by BMJ Publishing Group Limited (BMJ) and may not have been peer-reviewed. Any opinions or recommendations discussed are solely those of the author(s) and are not endorsed by BMJ. BMJ disclaims all liability and responsibility arising from any reliance placed on the content. Where the content includes any translated material, BMJ does not warrant the accuracy and reliability of the translations (including but not limited to local regulations, clinical guidelines, terminology, drug names and drug dosages), and is not responsible for any error and/or omissions arising from translation and adaptation or otherwise.

Open access This is an open access article distributed in accordance with the Creative Commons Attribution Non Commercial (CC BY-NC 4.0) license, which permits others to distribute, remix, adapt, build upon this work non-commercially, and license their derivative works on different terms, provided the original work is properly cited, appropriate credit is given, any changes made indicated, and the use is non-commercial. See: <http://creativecommons.org/licenses/by-nc/4.0/>.

ORCID iDs

Ji Hye Jang <http://orcid.org/0000-0002-9501-9892>

Sang Jun Park <http://orcid.org/0000-0003-0542-2758>

Se Joon Woo <http://orcid.org/0000-0003-3692-7169>

Yoo-Ri Chung <http://orcid.org/0000-0002-6871-6721>

REFERENCES

- 1 Hartnett ME. Advances in understanding and management of retinopathy of prematurity. *Surv Ophthalmol* 2017;62:S0039-6257(16)30114-X:257–76..
- 2 Lepore D, Molle F, Pagliara MM, et al. Atlas of fluorescein angiographic findings in eyes undergoing laser for retinopathy of prematurity. *Ophthalmology* 2011;118:168–75.
- 3 Solebo AL, Teoh L, Rahi J. Epidemiology of blindness in children. *Arch Dis Child* 2017;102:853–7.
- 4 Jang JH, Kim YC. Retinal vascular development in an immature retina at 33–34 weeks postmenstrual age predicts retinopathy of prematurity. *Sci Rep* 2020;10:18111.
- 5 Bellsmith KN, Brown J, Kim SJ, et al. Aggressive posterior retinopathy of prematurity: clinical and quantitative imaging features in a large north american cohort. *Ophthalmology* 2020;127:1105–12.
- 6 Cheng QE, Quinn GE, Daniel E, et al. Progression from preplus to plus disease in the telemedicine approaches to evaluating acute-phase retinopathy of prematurity (e-ROP) study: incidence, timing, and predictors. *J AAPOS* 2020;24:354.
- 7 Chiang MF, Quinn GE, Fielder AR, et al. International classification of retinopathy of prematurity, third edition. *Ophthalmology* 2021;128:e51–68.
- 8 Mintz-Hittner HA, Kennedy KA, Chuang AZ, et al. Efficacy of intravitreal bevacizumab for stage 3+ retinopathy of prematurity. *N Engl J Med* 2011;364:603–15.
- 9 Stahl A, Lepore D, Fielder A, et al. Ranibizumab versus laser therapy for the treatment of very low birthweight infants with retinopathy of prematurity (rainbow): an open-label randomised controlled trial. *Lancet* 2019;394:1551–9.
- 10 Chen TA, Shields RA, Bodnar ZH, et al. A spectrum of regression following intravitreal bevacizumab in retinopathy of prematurity. *Am J Ophthalmol* 2019;198:63–9.
- 11 Mintz-Hittner HA, Geloneck MM, Chuang AZ. Clinical management of recurrent retinopathy of prematurity after intravitreal bevacizumab monotherapy. *Ophthalmology* 2016;123:1845–55.
- 12 Good WV. Early treatment for retinopathy of prematurity cooperative group. final results of the early treatment for retinopathy of prematurity (ETROP) randomized trial. *Trans Am Ophthalmol Soc* 2004;102:233–48.
- 13 Hartnett ME. Vascular endothelial growth factor antagonist therapy for retinopathy of prematurity. *Clin Perinatol* 2014;41:925–43.
- 14 Sankar MJ, Sankar J, Chandra P. Anti-Vascular endothelial growth factor (VEGF) drugs for treatment of retinopathy of prematurity. *Cochrane Database Syst Rev* 2018;1:CD009734.
- 15 Vedantham V. Intravitreal aflibercept injection in Indian eyes with retinopathy of prematurity. *Indian J Ophthalmol* 2019;67:884–8.
- 16 Ekinci DY, Çelik K. Comparison of the efficacy between intravitreal aflibercept and laser photocoagulation in the treatment of retinopathy of prematurity. *J Pediatr Ophthalmol Strabismus* 2020;57:54–60.
- 17 Adams GGW, Bunce C, Xing W, et al. Treatment trends for retinopathy of prematurity in the UK: active surveillance study of infants at risk. *BMJ Open* 2017;7:e013366.
- 18 Prakalapakorn SG, Greenberg L, Edwards EM, et al. Trends in retinopathy of prematurity screening and treatment: 2008–2018. *Pediatrics* 2021;147:e2020039966.
- 19 Fukushima Y, Kawasaki R, Sakaguchi H, et al. Characterization of the progression pattern in retinopathy of prematurity subtypes. *Ophthalmol Retina* 2020;4:231–7.
- 20 Shin DH, Kong M, Kim SJ, et al. Risk factors and rate of progression for zone I versus zone II type 1 retinopathy of prematurity. *J AAPOS* 2014;18:124–8.
- 21 Çómez A, Karaküçük Y, Özmen MC, et al. The results of intravitreal bevacizumab monotherapy for treating aggressive posterior retinopathy of prematurity and type 1 retinopathy of prematurity. *Eye (Lond)* 2021;35:3302–10.
- 22 Roohipour R, Torabi H, Karkhaneh R, et al. Comparison of intravitreal bevacizumab injection and laser photocoagulation for type 1 zone II retinopathy of prematurity. *J Curr Ophthalmol* 2019;31:61–5.
- 23 Kumawat D, Sachan A, Shah P, et al. Aggressive posterior retinopathy of prematurity: a review on current understanding. *Eye (Lond)* 2021;35:1140–58.
- 24 Wang S-D, Zhang G-M, Shenzhen Screening for Retinopathy of Prematurity Cooperative Group. Laser therapy versus intravitreal injection of anti-VEGF agents in monotherapy of ROP: a meta-analysis. *Int J Ophthalmol* 2020;13:806–15.
- 25 Narnaware SH, Bawankule PK, Raje D. Aggressive posterior retinopathy of prematurity (APROP): laser as the primary modality of treatment. *J Ophthalmic Vis Res* 2021;16:400–7.
- 26 García-Quintanilla L, Luaces-Rodríguez A, Gil-Martínez M, et al. Pharmacokinetics of intravitreal anti-VEGF drugs in age-related macular degeneration. *Pharmaceutics* 2019;11:365.
- 27 Kong L, Bhatt AR, Demny AB, et al. Pharmacokinetics of bevacizumab and its effects on serum VEGF and IGF-1 in infants with retinopathy of prematurity. *Invest Ophthalmol Vis Sci* 2015;56:956–61.
- 28 Hong YR, Kim YH, Kim SY, et al. Plasma concentrations of vascular endothelial growth factor in retinopathy of prematurity after intravitreal bevacizumab injection. *Retina* 2015;35:1772–7.
- 29 Xu L, Lu T, Tuomi L, et al. Pharmacokinetics of ranibizumab in patients with neovascular age-related macular degeneration: a population approach. *Invest Ophthalmol Vis Sci* 2013;54:1616–24.
- 30 Fidler M, Fleck BW, Stahl A, et al. Ranibizumab population pharmacokinetics and free VEGF pharmacodynamics in preterm infants with retinopathy of prematurity in the rainbow trial. *Transl Vis Sci Technol* 2020;9:43.
- 31 Avery RL. Bevacizumab (Avastin) for retinopathy of prematurity: wrong dose, wrong drug, or both? *J AAPOS* 2012;16:2–4.
- 32 Wallace DK, Kraker RT, Freedman SF, et al. Assessment of lower doses of intravitreal bevacizumab for retinopathy of prematurity: a phase 1 dosing study. *JAMA Ophthalmol* 2017;135:654–6.
- 33 Stahl A, Krohne TU, Eter N, et al. Comparing alternative ranibizumab dosages for safety and efficacy in retinopathy of prematurity: a randomized clinical trial. *JAMA Pediatr* 2018;172:278–86.
- 34 Sukgen EA, Koçluk Y. The vascularization process after intravitreal ranibizumab injections for aggressive posterior retinopathy of prematurity. *Arq Bras Oftalmol* 2017;80:30–4.
- 35 Li X-J, Yang X-P, Sun S, et al. Intravitreal ranibizumab for aggressive posterior retinopathy of prematurity. *Chin Med J (Engl)* 2016;129:2879–81.
- 36 Tong Q, Yin H, Zhao M, et al. Outcomes and prognostic factors for aggressive posterior retinopathy of prematurity following initial treatment with intravitreal ranibizumab. *BMC Ophthalmol* 2018;18:150.
- 37 Valikodath NG, Chiang MF, Chan RVP. Description and management of retinopathy of prematurity reactivation after intravitreal antivascular endothelial growth factor therapy. *Curr Opin Ophthalmol* 2021;32:468–74.
- 38 Patel SN, Klufas MA. Evidence to date: ranibizumab and its potential in the treatment of retinopathy of prematurity. *Eye Brain* 2019;11:25–35.
- 39 Fleck BW, Reynolds JD, Zhu Q, et al. Time course of retinopathy of prematurity regression and reactivation after treatment with ranibizumab or laser in the rainbow trial. *Ophthalmol Retina* 2022;6:628–37.
- 40 Martínez-Castellanos MA, González-H León A, Romo-Aguas JC, et al. A proposal of an algorithm for the diagnosis and treatment of recurrence or treatment failure of retinopathy of prematurity after anti-VEGF therapy based on a large case series. *Graefes Arch Clin Exp Ophthalmol* 2020;258:767–72.

Supplemental Figure 1. Flow diagram illustrating the enrollment process