BMJ Open Ophthalmology

Indications and outcomes of vitrectomy surgery in a series of 1000 black African eyes

Ogugua Ndubuisi Okonkwo,[1,2] Karinya Lewis,[2] Adekunle Olubola Hassan,[1,2] Micheal Ekuoba Gyasi,[3] Banji Oluyadi,[2] Adunola Ogunro,[2] Olufemi Oderinlo,[1,2] Mildred Ulaikere[2]

To cite: Okonkwo ON, Lewis K, Hassan AO, *et al*. Indications and outcomes of vitrectomy surgery in a series of 1000 black African eyes. *BMJ Open Ophthalmology* 2019;**4**:e000083. doi:10.1136/bmjophth-2017-000083

Received 31 March 2017
Revised 18 December 2018
Accepted 29 January 2019

[1]Eye Foundation Retina Institute, Eye Foundation Center, Lagos, Nigeria
[2]Ophthalmology, Eye Foundation Hospital, Lagos, Nigeria
[3]Ophthalmology, St Thomas Eye Hospital, Accra, Ghana

Correspondence to
Dr Ogugua Ndubuisi Okonkwo; o_okonkwo@yahoo.com

ABSTRACT

Objective To determine the common indications for, and outcomes of pars plana vitrectomy surgery among black Africans in a low-resource setting.

Methods and Analysis A retrospective, non-comparative case review was undertaken. Data from 1000 consecutive eyes of 1000 patients in a single centre who underwent pars plana vitrectomy surgery between May 2005 and July 2013 were used for the study. Demographic data, primary indication for surgery, ocular status and outcomes were assessed.

Results Rhegmatogenous retinal detachment was the most common primary indication occurring in 61.8% of eyes. Diabetic vitrectomy, trauma and proliferative sickle cell retinopathy were also common indications occurring in 10.1%, 6.1% and 4.5% of eyes, respectively. At presentation, 33% of patients with retinal detachment had some form of proliferative vitreoretinopathy, and half of those had the more advanced grades C and D. Patients presented on an average of 13.5 months after onset of symptoms. As a result, visual outcomes were less than other reported studies.

Conclusion Retinal detachment was the most common indication for vitrectomy, but even these cases presented late with an advanced presentation. This study highlights the need for affordable and accessible vitreoretinal services in Sub-Saharan Africa and increased awareness of general eye health, along with strategies to reduce trauma and identify early those at risk of chronic eye diseases, such as diabetic retinopathy and sickle cell retinopathy.

Key messages

What is already known about this subject?

- There is limited information and publication on vitreoretinal surgical services in black Sub-Saharan Africa.
- Few vitreoretinal units exist in the region and several countries have no vitreoretinal service present.
- While blindness prevalence studies in the region focus on the more treatable causes of vision impairment such as cataract, the need for vitreoretinal surgeons and role of vitreoretinal services is under-recognised.

What are the new findings?

- This study establishes that rhegmatogenous retinal detachment and proliferative diabetic retinopathy are a significant problem requiring vitreoretinal intervention.
- Proliferative vitreoretinopathy rates reported in this study are more than is reported in wealthier nations and reflect delayed presentation, contributing to poorer outcomes after vitrectomy.
- Also, diabetic vitrectomy features as an important indication in the region, while macular hole (which is a priority in the more advanced nations) is a less common indication.

How might these results change the focus of research or clinical practice?

- The focus following this study should be on changing the behaviour of patients and physicians in the region through education, and also promoting earlier presentation and management of retinal detachment cases.
- We make a case for a more aggressive approach in preventing retinal detachment, by promoting retinal prophylaxis, for example, use of laser photocoagulation or cryotherapy to treat predisposing retinal lesions and retinal tears.
- Healthcare systems in the region should focus on establishing and promoting viable diabetic retinopathy screening programmes and timely retinal laser intervention, which may ultimately reduce the need for diabetic vitrectomy.

INTRODUCTION

Vitrectomy as a surgical procedure was first performed in a human eye in 1970, but since then has become very useful in combination with other procedures to treat many vitreoretinal (VR) conditions, restoring sight and preventing blinding complications in many eyes.[1] Refinements in technique and instrumentation have also led to confidence in earlier intervention and increasing numbers being performed worldwide.[2–4] However, the cost of viewing systems, instruments, consumables and maintenance required for vitrectomy is much higher than for other ophthalmic interventions. As a result, in Africa, there are very few ophthalmology centres providing comprehensive VR service, limiting access for patients who need the service and local

training opportunities in this subspecialty. Subsequently data on indications, presentation and outcomes of vitrectomy in this population are few and far between. A key paper, in 2002, reviewing retinal detachment outcomes in East Africa by Yorston *et al*,[5] highlighted the late presentation of patients in Africa and advocated the need for more VR services. However there have been few papers since that time. One of such studies is the paper from Ethiopia, which describes the clinical presentation of retinal detachment.[6]

This study aims to capture the experience of a single-centre VR team who together have performed over 1000 vitrectomies between 2005 and 2013 as a starting point for identifying further priorities for research, training and developments in this subspecialty.

METHODS

A retrospective, non-comparative consecutive case series was performed involving a thousand consecutive eyes that underwent a vitrectomy surgery from May 2005 to July 2013 at the Eye Foundation Retina Institute, Lagos, Nigeria. The Eye Foundation Retina Institute is a department of the Eye Foundation Hospital, which is an indigenous private training institution that comprises multispecialty eye clinics and surgeries. The Eye Foundation Retina Institute receives VR referrals from other eye centres within the state of Lagos and the country. There are a total of five VR centres in Lagos, serving an approximate population of 20 million. The majority of the patients pay privately for their eye care, while others may be sponsored, use health insurance or request for low-cost services.

The case records of the study patients were identified from the operating room log, and information from the case records was extracted. When a case record was not available or was missing, the next in the series was selected. All non-blacks were excluded. The primary information extracted was indication for surgery, outcomes and complications. In a situation where more than one indication for vitrectomy surgery was noted, the most significant indication was chosen as the primary indication.

Other information extracted included the patient's gender, laterality, visual acuity of the index eye and the fellow eye, symptom duration before presentation, duration of follow-up and number of revitrectomies. When retinal detachment was the primary indication, additional information including the presence of any proliferative vitreoretinopathy (PVR) and also of advanced PVR that is grade C or D and giant retinal tear (GRT) was noted. PVR grade C in this study was defined as the presence of fixed retinal folds, and grade D the presence of a funnel-shaped total retinal detachment. Also, intraoperative combination with cataract extraction, scleral buckle and use of endotamponade was also noted. Retina laser photocoagulation was the method of retinopexy in all cases. Cryotherapy was not used.

All surgeries were performed using the Accurus vitrectomy system (Alcon), and mostly 20G surgery was performed by the same VR team consisting of one senior consultant and two junior consultants. Over the study period, there were significant upgrades in technique and instrumentation (such as the change to transconjunctival surgery, the use of smaller gauge cutters and more recent wider angle viewing systems). Silicone oil was most commonly used as it was more available than expansile gases during the study period.

Table 1 Indications and frequency for 1000 vitrectomy cases.

Indication for surgery (diagnosis)	No of eyes	Percentage (%)
Rhegmatogenous Retinal Detachment (RRD)	618	61.8
Diabetic Retinopathy (DR)	101	10.1
Trauma	61	6.1
Proliferative Sickle Cell Retinopathy (PSCR)	45	4.5
Branch Retina Vein Occlusion (BRVO)	29	2.9
Endophthalmitis	19	1.9
Vitritis	19	1.9
Posterior Vitreous Detachment with Vitreous Haemorrhage	18	1.8
Macular Hole	16	1.6
Central Retina Vein Occlusion (CRVO)	14	1.4
Dislocated Lens	14	1.4
Cataract related Vitrectomies	12	1.2
Polypoidal Choroidal Vasculopathy	11	1.1
Macular Degeneration	8	0.8
Vitreous Haemorrhage from unknown cause	8	0.8
Tractional Retina Detachment with unknown cause	4	0.4
Dropped Nucleus	1	0.1
Vitreoretina Fibrosis	1	0.1
Asteroid Hyalosis	1	0.1
	1000	100.0

RESULTS

Of the 1000 eyes that had vitrectomy, 18 case records were missing, but were replaced with the next in line in the series. The overall age of patients seen ranged from 1 to 85 years (the average age was 47 years, with 709 males and 291 females (ratio 2.4:1)).

Of the one thousand vitrectomy surgeries performed within the study period, the top three indications for surgery were rhegmatogenous retinal detachment (62%), followed by diabetic retinopathy (DR) (10%) and trauma (6%), and this is illustrated in table 1. Vitreous

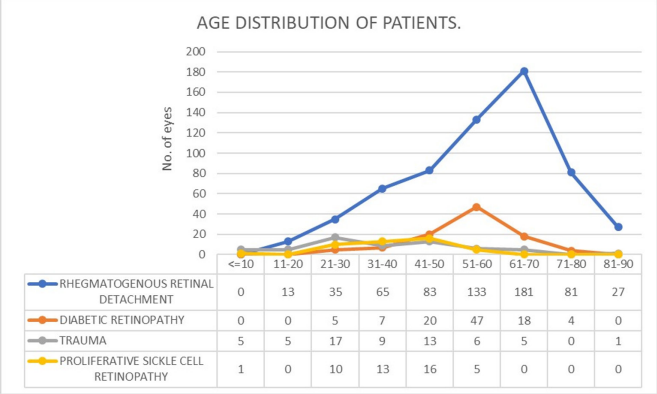

Figure 1 Age distribution and the number of eyes for the four most common indications for vitrectomy (rhegmatogenous retinal detachment, diabetic retinopathy, trauma and proliferative sickle cell retinopathy).

haemorrhage (VH) secondary to sickle cell proliferative retinopathy and branch vein occlusions were the next most common indication for vitrectomy (5% and 3%, respectively). Endophthalmitis, vitritis, haemorrhagic posterior vitreous detachment, macular hole, dislocated lens, trauma and cataract-related vitrectomy were less common indications, each accounting for about 1% of patients. Rare indications, occurring in less than 1% of cases, included macular degeneration, polypoidal choroidal vasculopathy, asteroid hyalosis, dropped nucleus, vitreous opacities and VR fibrosis. Details of indications and number of eyes are shown in table 1.

Figure 1 shows the age distribution curve of the four most common indications for surgery, which are rhegmatogenous retinal detachment, diabetic vitrectomy, trauma and proliferative sickle cell retinopathy.

A subanalysis of the two most common indications was done, comparing demographics, presentation, outcomes and complications.

Rhegmatogenous retinal detachment

Demographics and presentation

There were 618 eyes which presented with rhegmatogenous retinal detachment (RRD), the demographic and presentation details of which are captured in table 2.

The duration of onset of symptoms to presentation was on average 13.5 months, with 43% of patients presenting within 1 month of symptoms.

One-third of RRD had some degree of PVR, and half of these cases with PVR had advanced stages of PVR. Macular 'on' was recorded in only 19 (3%) of 618 eyes, and the remaining 97% were macular 'off' at presentation. Macular hole was seen in 52 eyes (8.3%). GRT was seen in 35 eyes (5.7%). Bullous retinal detachment was present in 34 eyes (5.5%), and some amount of VH was associated with the retinal detachment in 67 (10.8%) eyes. Silicone oil was used as endotamponade in 570 eyes (92.2%), and a scleral buckle was combined with vitrectomy in 31 (5%) of eyes. There were 588 (95.1%) eyes with a follow-up of over 2 months, while only 30 eyes had less than 2 months of follow-up. The primary retinal reattachment rate among these 588 eyes after 2 months was 56%. With further surgery, the final reattachment rate at the time of last clinic visit for all patients was 88.3% in 546 eyes.

RRD visual outcomes

A quarter of the eyes (158, 25.5%) had a visual acuity of 6/60 or better postoperatively (as shown in table 3) compared with only 138 (22%) preoperatively. A majority of eyes, however, had counting fingers vision or more and could navigate. Hand motion vision or worse was seen in 272 eyes (44%) postoperatively (table 3).

The visual acuity at presentation (preoperative vision of the operated eye) versus the postoperative vision for RRD eyes is shown in a scatter plot in figure 2.

RRD complications

As shown in table 4, 313 (50%) eyes with RRD required more than one vitrectomy to attach the retina. With further surgery, the final reattachment rate was 88.3% at the time of last clinic visit. The retina remained detached in 60 (9.5%) eyes, and there were 12 eyes (1.9%) in which the retina status could not be ascertained. Only 41.7% of the eyes had silicone oil removal. Some of the patients did not keep their postoperative scheduled clinic visits, and therefore silicone oil removal was not conducted at our facility and may have been done elsewhere. Of the 258 eyes that had the silicone oil removed, 225 (87.2%) had an attached retina as at the last follow-up. Silicone oil caused complications in 225 eyes (39%), with some patients having more than one complication.

Vitrectomy for diabetic retinopathy (DR)

DR was the second most common indication for vitrectomy, occurring in 101 eyes (10%). The age distribution of patients with diabetes is shown in figure 1 and is similar to patients with RRD, peaking in the 50s–60s age group. In patients with DR, vitrectomy was necessary to treat VH alone in 66 eyes (74%), tractional retinal detachment

Table 2 Demographics and presentation of patients with retinal detachment

	Peak age range, years	Gender male:female (%)	Right eye	Left eye	Mean duration of onset to surgery (months)	Patients presenting <1 month	1–6 months	>6 months	Any PVR	Advanced PVR
Retinal detachment (n=618)	51–70 years (50%)	71:29	340 (55%)	278 (45%)	13.5	265 (43%)	159 (26%)	192 (31%)	205 (33%)	102 (16.5%) (grade C: 68; grade D: 34)

PVR, proliferative vitreoretinopathy.

Table 3 Postoperative visual outcomes from vitrectomy

Postoperative visual outcome compared with preoperative	TRD±VH n=35		VH only n=66		PDR (all) n=101		Retinal detachment n=618	
	Eyes (n)	%	Eyes (n)	%	Eyes (n)	%	Eyes (n)	%
Visual acuity								
≥6/60 vision	5	14	35	53	40	39.5	158	26
Counting fingers vision	8	23	15	23	23	22.5	185	30
Hand movement or worse	22	63	16	24	38	38	272	44
Visual change								
Worse vision	14	40	14	21	28	27.5	201	32.5
Same vision	13	37	13	20	26	25.5	172	27.5
Improved vision	8	23	39	59	47	47	245	40

PDR, Proliferative Diabetic Retinopathy; TRD, tractional retinal detachment; VH, vitreous haemorrhage.

(TRD) with VH in 21 eyes (19.1%) and TRD only in 14 eyes (6.7%).

Fifty-two per cent of patients with DR had poor vision in the fellow eye, with a visual acuity of less than 6/60 in the fellow eye (53 eyes), compared with patients with RRD in whom only a third had poor vision in the other eye. This may suggest that health-seeking behaviour may depend more on patients' ability to function when the second eye is affected rather than the symptoms themselves.

PVR was noted in three eyes preoperatively, and silicone oil was used as endotamponade in 62 eyes (61.4%). Repeat vitrectomy was performed in 56.4% (57 eyes).

Visual acuity outcomes are reported in table 3 and subdivided into those who had VH alone and TRD with or without vitreous haemorrhage (±VH) as they represent different stages of the disease. Expectedly, the eyes with VH alone showed the greatest vision improvement, with 39 eyes (59%) improving compared with only 8 eyes (23%) in the TRD±VH group. The majority of eyes however, preserved counting fingers visual acuity which is sufficient for navigation.

The visual acuity at presentation (preoperative vision of the operated eye) versus the postoperative vision in DR eyes is presented as a scatter plot and is shown in figure 3.

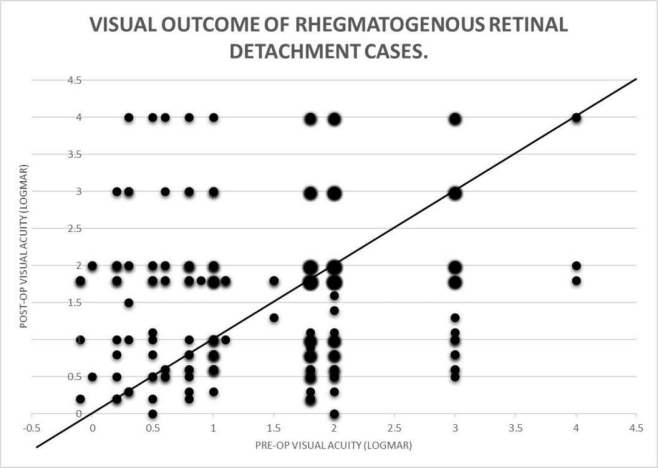

Figure 2 Comparison of preoperative versus postoperative visual acuity outcome of rhegmatogenous retinal detachment eyes. LOGMAR, logarithm of the minimum angle of resolution.

DISCUSSION

This study represents the largest consecutive case series of vitrectomies in Africa and offers insights into the clinical

Table 4 Complications of vitrectomy for RRD (n=618)

Complications	Percentage of RRD cases	Eyes (n)
Retinal attachment failure		
Primary failure to attach at 2 months	50	313
Revitrectomy ×1	37	226
Revitrectomy ×2	11	67
Revitrectomy ×3	3	19
Revitrectomy ×4	0.6	4
Revitrectomy ×6	0.2	1
Complete failure to attach	9.7	60
Final retinal attachment status undetermined	1.9	12
Overall reattachment rate	88.3	546
Tamponade used		
Silicone oil use	92.2	570
Intraocular gas and air	7.8	48
Scleral buckle use	5	31
Silicone oil complications		
Emulsified oil in AC	10	63
Raised intraocular pressure	24	148
Keratopathy	7.2	45
Number of complications from silicone oil use	56	345
Silicone oil removal	42	258

AC, Anterior Chamber; RRD, rhegmatogenous retinal detachment.

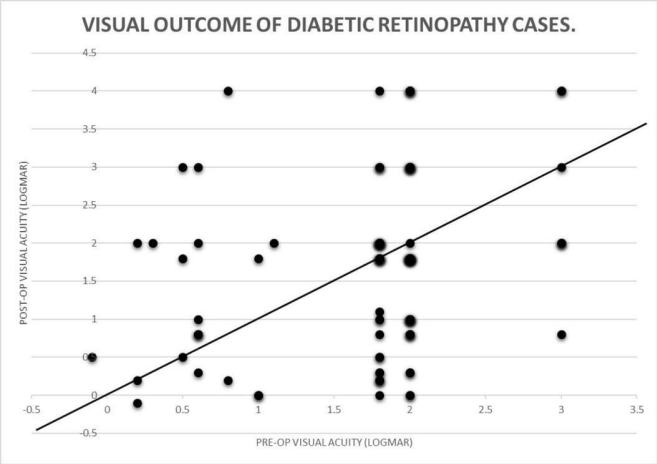

Figure 3 Comparison of preoperative versus postoperative visual acuity outcome of diabetic retinopathy eyes. LOGMAR, logarithm of the minimum angle of resolution.

presentation and outcomes of this surgery. As a retrospective case series, it lacks controls that would enable it to be compared directly with outcomes in a more developed continent. Equally, the study was performed in a single centre in Nigeria and may not be generalisable to all of Africa, given the variation in ethnicity, disease and surgical practice. Additionally, collecting data from a team of surgeons, of whom two were more junior, may also have introduced interoperation variability and affected surgical outcomes. The study was also conducted over a period of 8 years, which coincidentally was a significant time globally for advancements in the vitrectomy technique, and so surgery was evolving over this time period.

Nevertheless, this paper adds a significant contribution to the literature by making available real-world outcomes, which may serve as a benchmark for others in Africa and drive the need for better outcomes and specialist training of VR surgeons and their teams.

Studies conducted in Africa report a variable incidence of VR diseases, but there are few population-based studies.[7–10] In the national Nigerian blindness survey, Kyari *et al* found that the age-adjusted prevalence of diabetes in Nigeria was 3.25% and that over 10% of people with diabetes aged ≥40 years had sight-threatening DR.[11 12] Trauma accounted for 1.1% of blindness, but retinal detachment was not specifically reported. With an ever-increasing population in Nigeria and the increasing prevalence of diabetes mellitus in Africa and worldwide, the need for retinal screening and VR services in Africa is essential.[11 13 14]

This study demonstrated that retinal detachment, while a low concern on a population basis, remains the most common indication for vitrectomy, with the possibility to prevent blindness. This supports the findings by Yorston *et al*, in 2002, who also highlighted the burden of retinal detachments and advocated for more resources and training.[5] However, this study also highlighted the fact that patients with retinal detachment come on average 13.5 months after the initial onset of symptoms and only 43% of patients came within the first month. This translates to a majority of patients (97%) presenting with macular involvement. Longer duration between symptoms and treatment has long been associated with poorer visual outcomes.[7] This study suggested that patients often presented only when their better eye deteriorated, as indicated by the high number of patients who had poor vision in the fellow eye for RRD, which was 28.9%, and for DR was 35%. Interestingly, regardless of indication for vitrectomy, a significantly higher proportion of males accessed VR services than females (80:20), which highlights the inequalities in healthcare access and supports the findings of the Nigerian national blindness survey which found that being female was a risk factor for blindness.[15]

The delay in presentation allows PVR to develop and is linked to poor prognosis. PVR was seen in a third of RRD eyes in this study and 16.5% of eyes had significant PVR (grades C and D). This is lower than what has been reported in a similar study from South Africa in which PVR was seen in 33% of the eyes.[16] The study from east Africa reported a similar PVR rate of 18%.[5] However, a study from Ethiopia having a much higher rate of significant PVR at 69% has been reported.[6] It is therefore safe to say that PVR rates in Africa vary widely but are in the double digits, contrary to findings in the more developed countries which have single-digit PVR rates.[17 18] This creates a significant challenge and complexity to retinal detachment presentation and treatment outcomes. Similarly, GRTs are more difficult to treat, and their frequency in this study (5.7%) and in Yorston's study (8.3%) suggests that GRTs are more common in Africa than in the UK.[19]

The advanced presentation of African patients with RRD begs the question what surgical technique is best used in these complex cases. Several studies have tried to answer this question, arguing that using scleral buckle alone might have better anatomical success rates, but the complexity of cases with PVR would support the necessity for vitrectomy with silicone oil.[20–22] In this series, vitrectomy rather than scleral buckle featured as the predominant technique, with only 5% of cases using additional buckle. Interestingly, the use of scleral buckle reduced and vitrectomy increased during the study period, similar to global trends as highlighted by the American Society of Retina Specialists (ASRS.org) Preferences and Trend (PAT) survey.

Final anatomical success was 88.3%, similar to the 88.2% reported in Kenya with patients having a similar amount of advanced PVR.[5] The visual outcome of the RRD eyes in this study is rather disappointing compared with the East Africa study where 63.7% had a vision of 6/60 or better. However their visual acuity results were reported for patients who achieved anatomical success, whereas our study reports on all retinal detachments. Our poor results could also be explained by the significant delay in patient presentation; almost all patients were macular off at presentation and that nearly 40% of

patients had complications from using silicone oil and as much as 41% of patients did not have the oil removed by the final clinic visit. Outcome of surgery using silicone oil has been shown to be poorer than with gas and has the added disadvantage of requiring a further procedure to remove the oil. Expansile gases are the way forward to improve vitrectomy outcomes for African patients, but collaborative efforts are needed to create reliable and affordable supply chains to VR units within Africa.

The visual outcomes in the DR were better than in the rhegmatogenous retinal detachment group, which is unsurprising given the indication in 60% of these vitrectomies was VH alone. However 40% of our patients had vision which was worse postoperatively compared with Guthrie *et al*,[23] whose study showed only 25% of patients with worse vision postoperatively. However a quarter of patients in Guthrie *et al*'s study were non-domicile and may represent different ethnicity. Mastropasqua *et al* have shown that black patients have poorer visual outcomes compared with white and Asian patients, and this may explain our outcomes in an exclusively black population.[24] A preoperative intravitreal injection of bevacizumab has been demonstrated by Guthrie *et al* in an African population to reduce intraoperative complications and reduce vision loss after vitrectomy.[23] However the additional cost incurred by the patient remains a challenge and has not been adopted as routine in our practice.

This study highlights the challenges faced by VR teams performing vitrectomies in Africa. There is still much to be improved on surgically, including improvements in techniques, equipment and training. However, to improve outcomes from vitrectomy, patients with VR problems need to be identified earlier and expansile gases used as the tamponade. In the case of RRD, patient awareness of symptoms needs to be raised at the community level to trigger early consultation at the primary level, followed by assessment and evaluation of the eye by health professionals, who with fundal mobile photography and digital technology, can communicate and refer patients to tertiary care.[25] For DR, a national screening programme of annual fundus examination for all patients with diabetes needs to be implemented to identify and treat proliferative disease early.

Contributors ONO, MEG and AOH designed and planned the study. ONO, AO and OO supervised the data collection and analysis. KL, MEG, BO, ONO and AOH wrote and reviewed the manuscript. ONO and MU submitted the manuscript.

Funding The authors have not declared a specific grant for this research from any funding agency in the public, commercial or not-for-profit sectors.

Competing interests None declared.

Patient consent for publication Not required.

Provenance and peer review Not commissioned; externally peer reviewed.

REFERENCES

1. Machemer R, Buettner H, Norton EW, *et al*. Vitrectomy: a pars plana approach. *Ophthalmol* 1971;75:813–20.
2. Fujii GY, De Juan Jr E, Humayun MS, *et al*. A new 25-gauge instrument system for transconjunctival sutureless vitrectomy surgery. *Ophthalmol* 2002;109:1807–12.
3. Eckardt C. Transconjunctival sutureless 23-gauge vitrectomy. *Retina* 2005;25:208–11.
4. Fujii GY, De Juan E, Humayun MS, *et al*. Initial experience using the transconjunctival sutureless vitrectomy system for vitreoretinal surgery. *Ophthalmol* 2002;109:1814–20.
5. Yorston DavidB, Wood ML, Gilbert C. Retinal detachment in East Africa. *Ophthalmology* 2002;109:2279–83.
6. Asaminew T, Gelaw Y, Bekele S, *et al*. Correction: retinal detachment in Southwest Ethiopia: a hospital based prospective study. *PLoS ONE* 2013;8.
7. Oderinlo O, Hassan AO, Okonkwo ON, *et al*. Factors influencing visual outcome after surgery for retinal detachment. *Niger J Ophthalmol* 2012;20:24–9.
8. Nwosu SN, Akudinobi C, Ndulue J. Incidence and pattern of retinal detachment in a tertiary eye hospital in Nigeria. *Niger J Ophthalmol* 2014;22:69–72.
9. Yorston D, Jalali S. Retinal detachment in developing countries. *Eye* 2002;16:353–8.
10. Burgess PI, Msukwa G, Beare NAV. Diabetic retinopathy in sub-Saharan Africa: meeting the challenges of an emerging epidemic. *BMC Med* 2013;11.
11. Abdull M, Sivasubramaniam A, Murthy GVS, *et al*. Visual impairment in Nigeria. The National blindness and visual impairment survey. *Investigative Ophthalmology and Visual Science. Sept* 2009;50:41114–4120.
12. Kyari F, Tafida A, Sivasubramaniam S, *et al*. Prevalence and risk factors for diabetes and diabetic retinopathy: results from the Nigeria national blindness and visual impairment survey. *BMC Public Health* 2014;14.
13. JWY Y, Rogers SL, Kawasaki R. Global prevalence and major risk factors of diabetic retinopathy. *Diabetes Care* 2012;35:556–64.
14. Hall V, Thomsen RW, Henriksen O, *et al*. Diabetes in sub Saharan Africa 1999-2011: epidemiology and public health implications. A systematic review. *BMC Public Health* 2011;11.
15. Kyari F, Gudlavalleti MVS, Sivsubramaniam S, *et al*. Prevalence of blindness and visual impairment in Nigeria: the National blindness and visual impairment survey. *Invest. Ophthalmol. Vis. Sci.* 2009;50:2033–9.
16. Peters AL. Retinal detachment in black South Africans. *S Afr Med J* 1995;85:158–9.
17. Comer MB, Newman DK, George ND, Martin KR, *et al*. Who should manage primary retinal detachments? *Eye* 2000;14:572–8.
18. Grizzard WS, Hilton GF, Hammer ME, *et al*. A multivariate analysis of anatomic success of retinal detachments treated with scleral buckling. *Graefe's Arch Clin Exp Ophthalmol* 1994;232:1–7.
19. Ang GS, Townend J, Lois N. Epidemiology of giant retinal tears in the United Kingdom: the British giant retinal tear epidemiology eye study (BGEES). *Invest. Ophthalmol. Vis. Sci.* 2010;51:4781–7.
20. Heimann H, Bartz-Schmidt KU, Bornfeld N, *et al*. Scleral buckling versus primary vitrectomy in rhegmatogenous retinal detachment. *Ophthalmology* 2007;114:2142–54.
21. Huang C, Fu T, Zhang T, *et al*. Scleral buckling versus vitrectomy for macula-off rhegmatogenous retinal detachment as accessed with spectral-domain optical coherence tomography: a retrospective observational case series. *BMC Ophthalmol* 2013;13.
22. Miki D*et al*. Comparison of scleral buckling and vitrectomy for retinal detachment resulting from flap tears in superior quadrants. *Japanese Journal of Ophthalmology* 2001;45:187–91.
23. Guthrie G, Hall AB, Dhalla K, *et al*. Bevacizumab as an adjunct to vitreoretinal surgery for diabetic retinopathy in East Africa. *Eye* 2013;27:1263–8.
24. Mastropasqua R, Luo YH-L, Cheah YS, *et al*. Black patients sustain vision loss while white and South Asian patients gain vision following delamination or segmentation surgery for tractional complications associated with proliferative diabetic retinopathy. *Eye* 2017;31:1468–74.
25. Bastawrous A, Giardini ME, Bolster NM, *et al*. Clinical validation of a smartphone-based adapter for optic disc imaging in Kenya. *JAMA Ophthalmol* 2016;134:151–8.