

Efficacy and safety of an extemporaneous preparation of 2% ganciclovir eye drops in CMV anterior uveitis

Narumon Keorochana, Raveewan Choontanom

To cite: Keorochana N, Choontanom R. Efficacy and safety of an extemporaneous preparation of 2% ganciclovir eye drops in CMV anterior uveitis. *BMJ Open Ophthalm* 2017;**2**:e000061. doi:10.1136/bmjophth-2016-000061

Received 29 November 2016
Revised 29 March 2017
Accepted 06 July 2017

ABSTRACT

Background To evaluate the efficacy and safety of an extemporaneous preparation of 2% ganciclovir topical eye drops in cytomegalovirus (CMV) anterior uveitis because many studies have confirmed the benefits of topical ganciclovir in varying concentrations.

Design The study employed a retrospective cohort design.

Methods This study enrolled 11 eyes (11 patients) with CMV anterior uveitis. All cases were proved by positive PCR for CMV DNA from aqueous tapping and received topical 2% ganciclovir, applied every 2 hours daily as induction therapy then tapered off and stopped based on clinical response. Outcome measures were best-corrected visual acuity, anterior chamber cell, coin-shaped and other keratic precipitates, intraocular pressure (IOP), the number of antiglaucoma drugs used, the frequency of steroid eye drops used daily and side effects over a 12-month follow-up period. Side effects after applying topical 2% ganciclovir were recorded using questionnaires and eye examination.

Results Mean age was 49.0 ± 17.8 years. IOP, number of antiglaucoma drugs used and keratic precipitates decreased significantly at first week ($p < 0.013$, $p < 0.024$ and $p < 0.031$, respectively) followed by decreased anterior chamber cells and significantly reduced frequency of applying steroid eye drops at 4 weeks ($p < 0.034$ and $p < 0.017$, respectively). Visual acuity significantly improved at 5 months continuously. All clinical improvement was maintained to 12 months, and keratic precipitates were eliminated in 90% of all cases. However, in 27% of discontinued medicine cases, inflammation was recurrent. No significance was observed in all factors between recurrent and non-recurrent groups. The most common side effect was eye irritation (27.27%). No severe complications from the medicine was detected.

Conclusion Extemporaneous preparation topical 2% ganciclovir was effective and safely controlled CMV anterior uveitis. The medication is non-invasive, economical and convenient for hospitals where commercial topical ganciclovir is unavailable.

INTRODUCTION

In the past, the known causes of infectious anterior uveitis in the herpesviridae

Key messages

- ▶ The treatment of cytomegalovirus (CMV) anterior uveitis with topical ganciclovir gained more popularity. The concentration of this medicine was variedly used.
- ▶ We reported the efficacy of topical 2% ganciclovir in timeline with safety information in these patients.
- ▶ The findings suggest that the use of extemporaneous preparation topical 2% ganciclovir could be alternatively employed where commercial topical ganciclovir is unavailable.

family¹ were only varicella zoster and herpes simplex types 1 and 2. Currently, cytomegalovirus (CMV) anterior uveitis and corneal endotheliitis were increasingly found among immunocompetent patients.² This increase is probably due to advanced modern investigations such as PCR that are able to detect and confirm the diagnosis of infectious uveitis.^{3–4} CMV anterior uveitis and corneal endotheliitis present anterior chamber inflammation, increased intraocular pressure (IOP), coin shaped lesions or other keratic precipitates (KPs) and iris atrophy.^{5–7} The diagnosis of CMV anterior uveitis is based on clinical manifestations and PCR results from the aqueous humour.^{8–11}

To treat CMV anterior uveitis, ganciclovir is a well-known medication used to suppress the replication of the herpes virus.¹² In the beginning, systemic ganciclovir, such as intravenous ganciclovir^{2–11} and oral valganciclovir,^{13–14} were recommended for CMV anterior uveitis. However, they are expensive and present the risk of systemic side effects like granulocytopenia, thrombocytopenia, anaemia, azoospermia and rising serum creatinine levels.¹⁵ Local ganciclovir therapy has become more popular for



CrossMark

Department of Ophthalmology, Phramongkutklao hospital, Phramongkutklao College of Medicine, Bangkok, Thailand

Correspondence to

Dr Narumon Keorochana; narumon_keo@hotmail.com

Table 1 Characteristics of patients

Patient no.	Age/ gender	Affected eye	History of ocular disease	Duration before CMV detection (months)	History of antiviral medication	History of topical antiviral medication
1	76/M	Left	–	57	Valganciclovir oral	0.15% Ganciclovir gel
2	38/M	Left	–	12	–	–
3	28/M	Left	–	18	–	–
4	59/M	Left	Corneal decompensate	57	IV ganciclovir	0.15% Ganciclovir gel
5	50/F	Right	–	204	–	–
6	53/M	Left	Primary open angle glaucoma	62	–	–
7	52/M	Right	–	62	–	–
8	41/M	Left	Behcet's disease on cyclophosphamide	1	IVT ganciclovir	–
9	33/F	Left	–	48	–	–
10	81/M	Left	S/P PKP	60	–	–
11	29/F	Right	S/P PKP	14	–	–

M, male; F, female; IV, intravenous; IVT, intravitreous; S/P PKP, post penetrating keratopathy.

producing fewer systemic side effects including intravitreal ganciclovir¹⁶ and topical ganciclovir. Many studies have confirmed the benefits of topical ganciclovir in varying concentrations from 0.15% ganciclovir^{17 18} and 0.5% ganciclovir^{16 19} to 2% ganciclovir.^{20 21} Commercial topical 0.15% ganciclovir gel is available in many countries; however, in some countries such as Thailand, it has not been imported yet. Therefore, we aimed to evaluate the efficacy of an extemporaneous

preparation of 2% ganciclovir eye drops and to determine its safety features as well.

METHODS

Medical records in the Ophthalmology Department of Phramongkutklo Hospital were retrospectively reviewed from January 2013 to August 2016. We enrolled 11 patients presented with anterior uveitis, coin-shaped lesions and other KPs, IOP including

Table 2 Characteristics of baseline

	n	Mean±SD	Median (min–max)	n (%)
Baseline				
Age	11	49.09±17.78	50 (28–81)	
Duration (months)	11	54.09±54.94	57 (1–204)	
Visual acuity	11	0.61±0.59	0.2 (0–1.4)	
Cell	11	0.73±1.13	0.5 (0–4)	
KPs				
No				1 (9.10)
Yes				10 (90.9)
IOP	11	26.73±10.42	28 (14–44)	
Antiglaucoma drug	11	3.00±1.67	3 (0–6)	
Steroid	11	5.45±4.20	4 (2–16)	

IOP, intraocular pressure; KP, keratic precipitate.

Table 3 Clinical manifestations of patients with CMV anterior uveitis included number of antiglaucoma drugs and frequency of steroid eye drops in a day before and after topical 2% ganciclovir therapy

Patient no.	Clinical before topical 2% ganciclovir				Clinical after topical 2% ganciclovir 12 months				Status of topical ganciclovir at 12 months	No. of recurrent	Trabeculectomy with mitomycin C				
	Visual acuity	Cell	KPs	IOP	G	S	Visual acuity	Cell				KPs	IOP	G	S
1	20/25	1+	+	17	3	4	20/25	0	–	17	2	0	Off	1	
2	20/32	0.5	+	30	4	4	20/20	0	–	16	1	1	Once a day	2	
3	20/20	0.5	+	32	2	10	20/20	0	–	12	0	0	Off	0	
4	20/60	1	+	28	4	2	20/25	0	–	11	1	0	Once a day	0	
5	20/40	0.5	+	13	4	4	20/25	0	–	10	0	2	Off (at 6 months)	1	9th month
6	20/32	0.5	+	40	3	6	20/20	0	+	13	0	0	Three times a day	1	
7	20/25	0	+	14	2	4	20/20	0	–	8	0	0	Three times a day	1	
8	HM	4+	–	33	6	16	20/200	0.5	–	16	2	4	Once a day	0	
9	20/100	0.5	+	44	4	4	20/50	0	–	6	0	0	Off	0	2nd month
10	FC2	0.5	+	15	1	4	HM	0	–	1	1	1	Off	0	
11	FC1	0	+	15	0	4	FC1'	0	–	17	2	4	Once a day (6 months)	1	

G, the number of antiglaucoma drugs.

S, the frequency of steroid drops per day.

CMV, cytomegalovirus; FC, finger count; HM, hand motion; IOP, intraocular pressure; KP, keratic precipitate.

Table 4 Clinical response of 2% ganciclovir eye drop compared with baseline 1 week–6 months

	Baseline Median (min–max)	1 week Median (min–max)	4 weeks Median (min–max)	2 months Median (min–max)	3 months Median (min–max)	4 months Median (min–max)	5 months Median (min–max)	6 months Median (min–max)
Visual acuity	0.2 (0–1.4)	0.3 (0–1.4) p = 0.031	0.5 (0–1.1) p = 0.095	0.2 (0–1.3) p = 0.078	0.4 (0–1.3) p = 0.065	0.2 (0–1.1) p = 0.065	0.2 (0–1.1) p = 0.020	0.1 (0–1.1) p = 0.011
Cell	0.5 (0–4)	0 (0–3) p = 0.058	0 (0–1) p = 0.034	0 (0–1) p = 0.020	0 (0–0.5) p = 0.007	0 (0–2) p = 0.008	0 (0–1) p = 0.034	0 (0–1) p = 0.007
IOP	28 (14–44)	13 (12–20) p = 0.013	15 (8–18) p = 0.012	14 (8–16) p = 0.006	11 (8–24) p = 0.11	14 (8–16) p = 0.005	14 (9–29) p = 0.012	14 (7–18) p = 0.003
Antiglaucoma drug	3 (0–6)	2 (0–5) p = 0.024	2 (0–4) p = 0.010	2 (0–4) p = 0.011	1 (0–3) p = 0.007	1 (0–4) p = 0.011	1 (0–4) p = 0.011	1 (0–3) p = 0.007
Steroid	4 (2–16)	4 (0–16) p = 0.176	2 (0–8) p = 0.017	2 (0–4) p = 0.018	2 (0–4) p = 0.11	2 (0–8) p = 0.005	2 (0–4) p = 0.007	1 (0–4) p = 0.005
KPs present 10 (90.9%)		4 (36.36%) p = 0.031	0 NA	0 NA	0 NA	0 NA	1 (9.09%) p = 0.004	0 NA

Wilcoxon signed-rank test.

McNemar test.

Significant (p<0.05).

IOP, intraocular pressure; KPs, keratic precipitates.

subjects with a history of using topical steroids and topical antiglaucoma drugs. All patients underwent aqueous tapping using PCR for seven types of herpes, and the results showed only positive for CMV. Patients

had a diagnosis of CMV anterior uveitis or corneal endotheliitis based on clinical manifestations and positive PCR results for CMV DNA from the aqueous humour. Patients were treated with topical 2% ganci-

Table 5 Response of 2% ganciclovir eye drop compared with baseline 7 months–12 months

	n	Baseline Median (min–max)	7 months Median (min–max)	8 months Median (min–max)	9 months Median (min–max)	10 months Median (min–max)	11 months Median (min–max)	12 months Median (min–max)
Visual acuity	9	0.2 (0–1.4)	0 (0–1.1) p = 0.017	0 (0–1.1) p = 0.017	0 (0–1.1) p = 0.017	0 (0–1.1) p = 0.017	0 (0–1.1) p = 0.017	0 (0–1.1) p = 0.017
Cell	9	0.5 (0–4)	0 (0–1) p = 0.034	0 (0–1) p = 0.008	0 (0–0.5) p = 0.021	0 (0–0) p = 0.008	0 (0–0.5) p = 0.014	0 (0–0.5) p = 0.008
IOP	9	28 (14–44)	14 (8–17) p = 0.013	12 (6–18) p = 0.011	12 (9–17) p = 0.008	15 (1–24) p = 0.021	14 (1–24) p = 0.018	12 (1–17) p = 0.012
Antiglaucoma drug	9	3 (1–6)	1 (0–2) p = 0.011	1 (0–2) p = 0.011	1 (0–2) p = 0.011	1 (0–2) p = 0.012	0 (0–2) p = 0.007	0 (0–2) p = 0.007
Steroid	9	4 (2–16)	0 (0–6) p = 0.024	0 (0–4) p = 0.012	0 (0–4) p = 0.012	0 (0–4) p = 0.011	0 (0–4) p = 0.016	0 (0–4) p = 0.011
KPs present	9	10 (90.9%)	1 (11.11%) p = 0.016	0 NA	1 (11.11%) p = 0.016	2 (22.22%) p = 0.031	2 (22.22%) p = 0.031	2 (22.22%) p = 0.031

Wilcoxon Signed-rank test.

McNemar test.

Significant (p<0.05).

IOP, intraocular pressure; KPs, keratic precipitates.

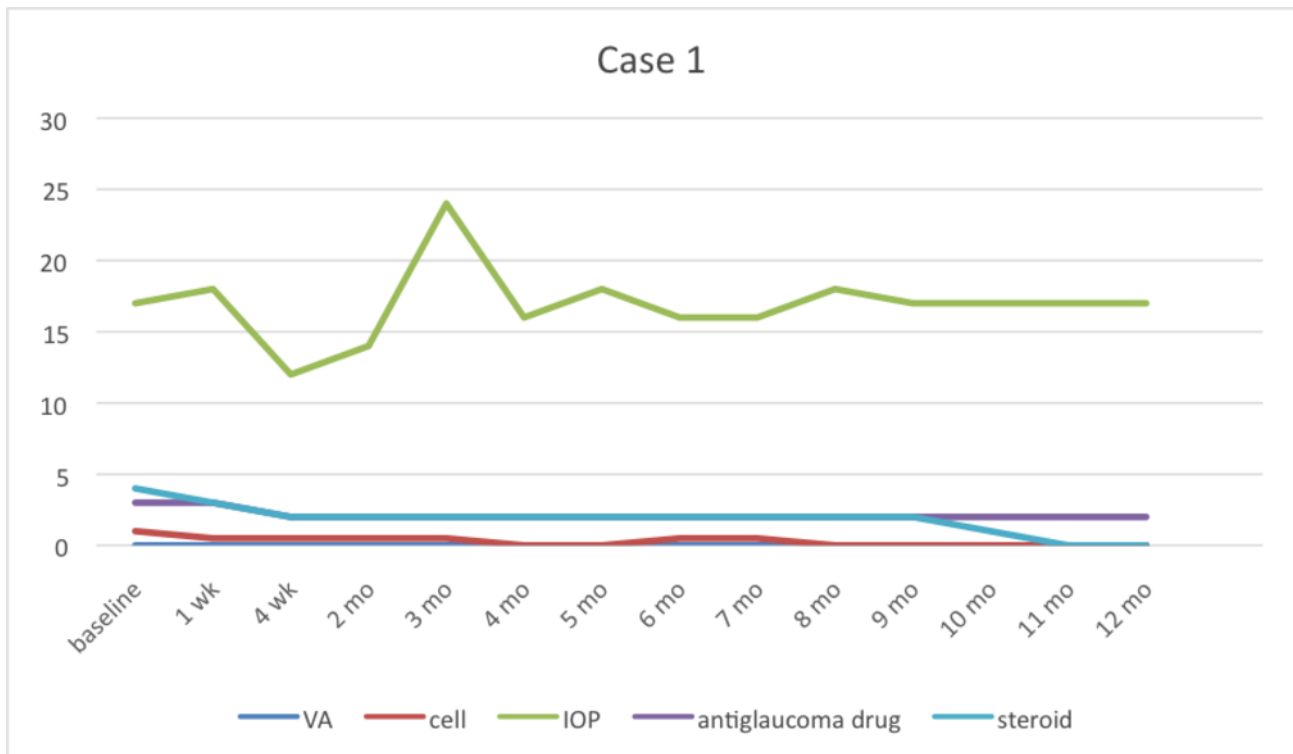


Figure 1 Case 1 had recurrent symptoms at the 3rd month then we stopped using topical 2% ganciclovir at 11th month. IOP, intraocular pressure; VA, visual acuity.

ganciclovir prepared from 500 mg of Cymevene IV lyophilised powder (Roch, Basel, Switzerland) in 25 mL of sterile water, at 20 mg/1 mL. The price per bottle was

57 GBP. Because this medicine comprises preservative-free eye drops, it expires within 1 month. Furthermore, patients were informed to keep their medication in a

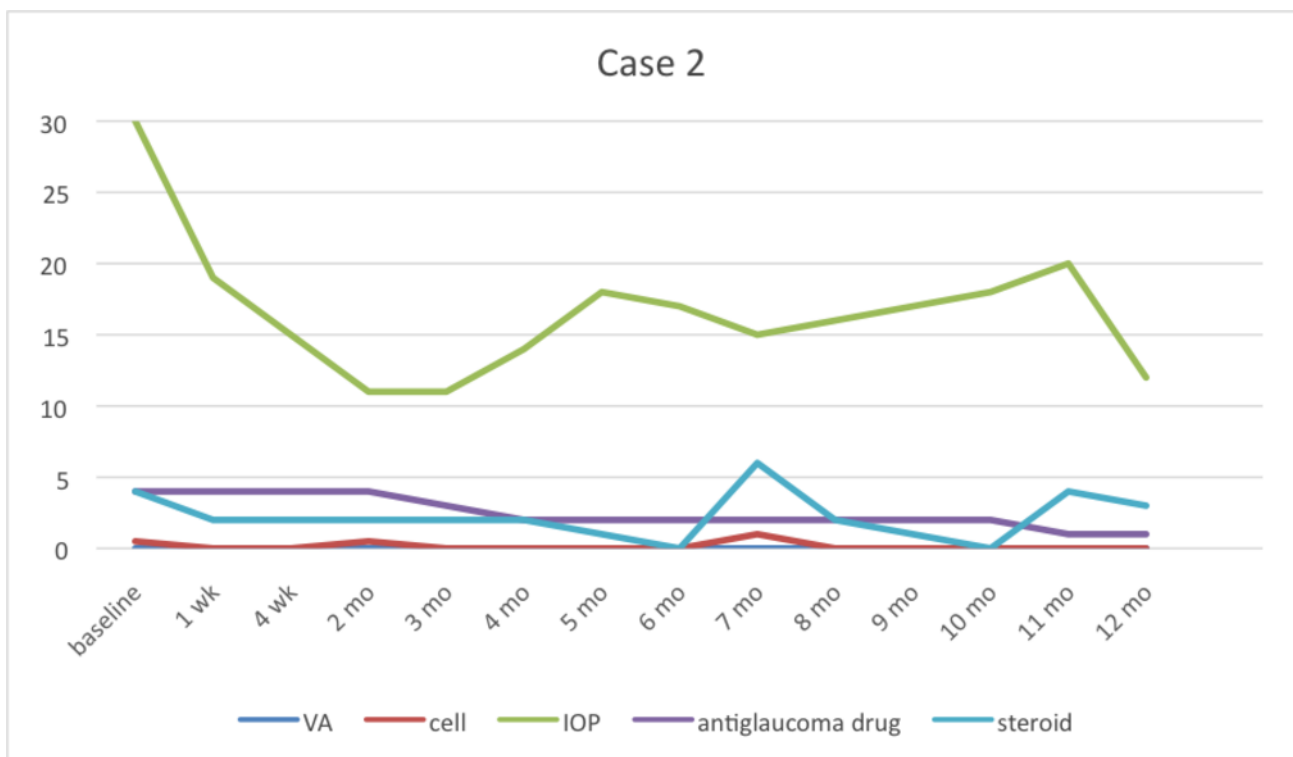


Figure 2 Case 2 had recurrent symptoms at the 7th and 11th months while tapering 2% topical ganciclovir. IOP, intraocular pressure; VA, visual acuity.

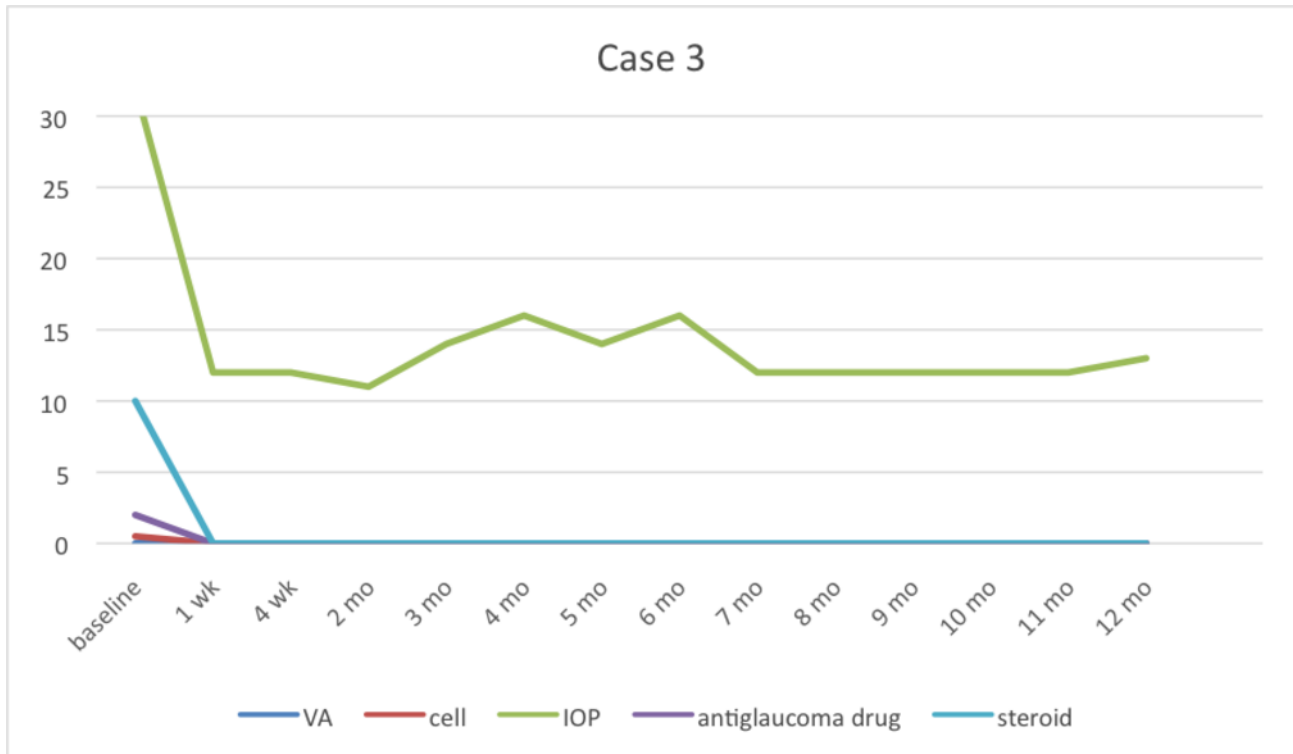


Figure 3 Case 3 could be stopped using 2% topical ganciclovir at 3rd month without any recurrent symptoms. IOP, intraocular pressure; VA, visual acuity.

brown medicine bottle and in a cool place (2°C–8°C) all the time. Topical 2% ganciclovir was prescribed to be applied every 2 hours daily as induction therapy for 2 weeks and after that tapering off to every 4 hours,

four times daily, three times daily, twice a day, once daily every week and finally stopped based on clinical response.

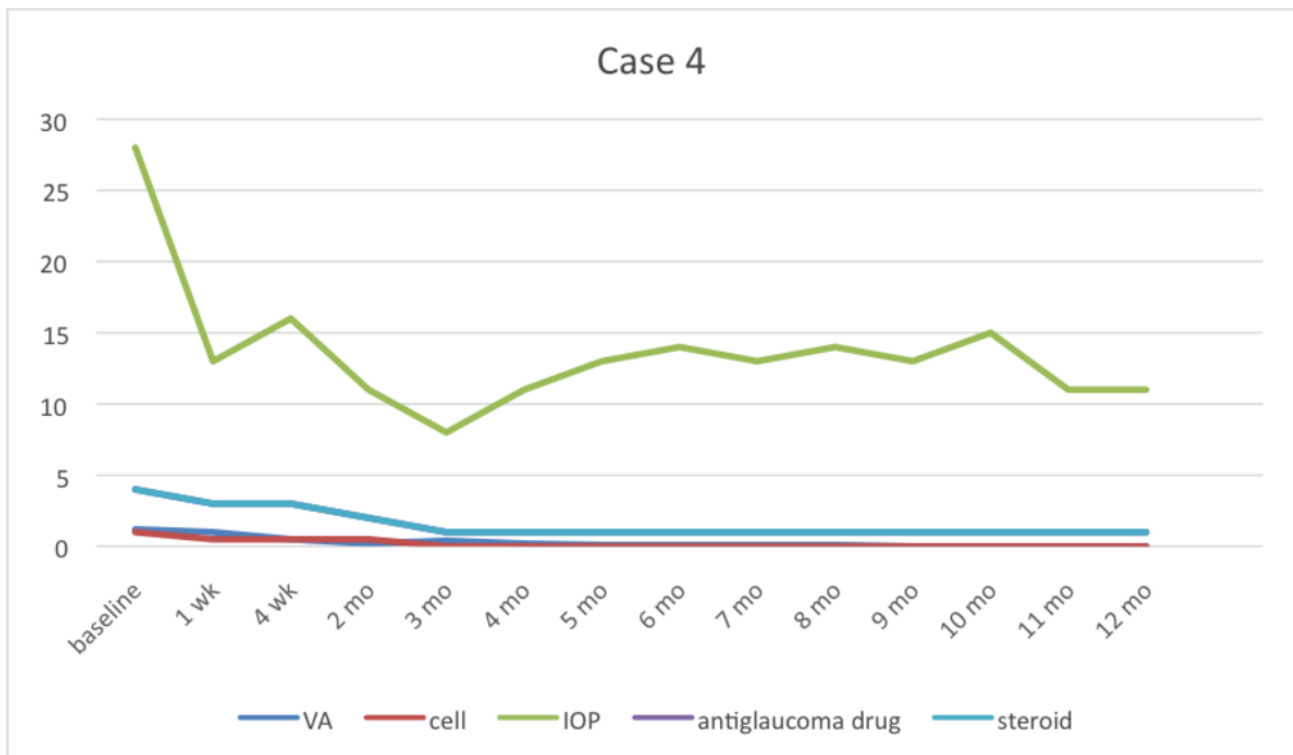


Figure 4 Case 4 (corneal decompensate) still continues topical ganciclovir four times a day for undergoing penetrating keratoplasty in the future. IOP, intraocular pressure; VA, visual acuity.

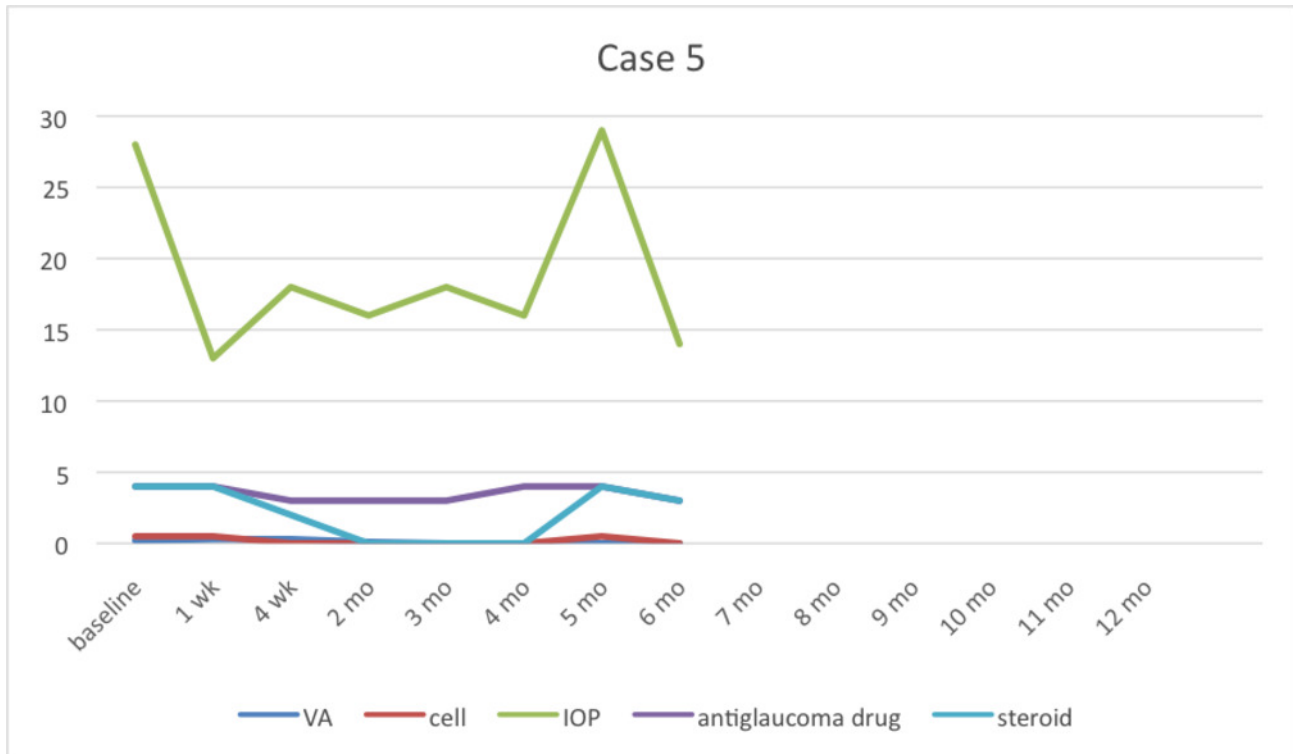


Figure 5 Case 5 had recurrent symptoms at fifth month and then finally the patient stopped taking medicine. IOP, intraocular pressure; VA, visual acuity.

The collected patient data comprised demographics as well as underlying disease and previous ocular treatment including number of topical steroids and antiglaucoma drugs used. Ophthalmic examinations

included best-corrected visual acuity (BCVA) using a Snellen eye chart, anterior chamber inflammation, KPs and IOP using Goldman applanation tonometry before and after treatment monthly. BCVA was converted to

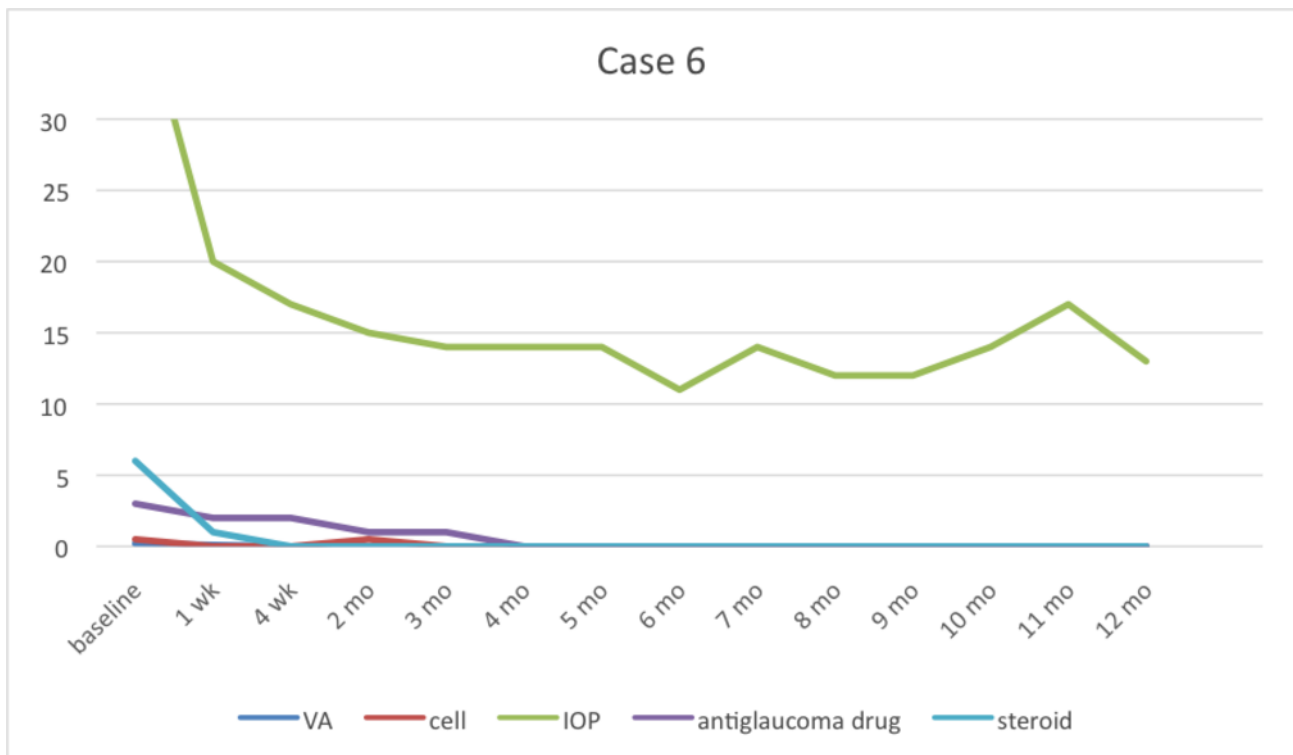


Figure 6 Case 6 stopped taking 2% topical ganciclovir at 7th month. After that the recurrent symptoms occurred at 10th month by the presenting of keratic precipitates. IOP, intraocular pressure; VA, visual acuity.

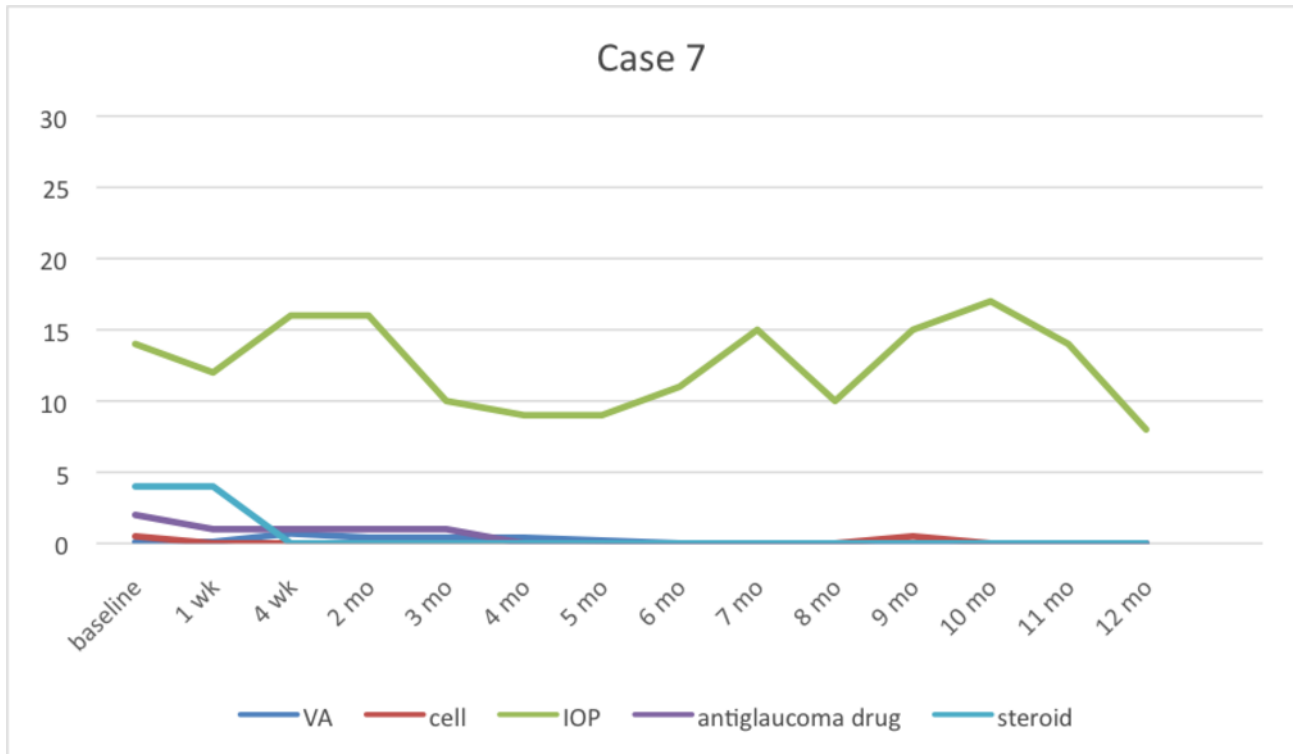


Figure 7 Case 7 stopped taking topical 2% ganciclovir at 6th month then recurrent symptoms occurred at 9th month. IOP, intraocular pressure. VA, visual acuity.

logMar to record. In addition, anterior chamber cells were graded using SUN classification.²² Antiglaucoma drugs were recorded by counting the number of

medications used while steroid use was recorded by counting the frequency of topical 1% prednisolone acetate or loteprednal eye drops in 1 day.

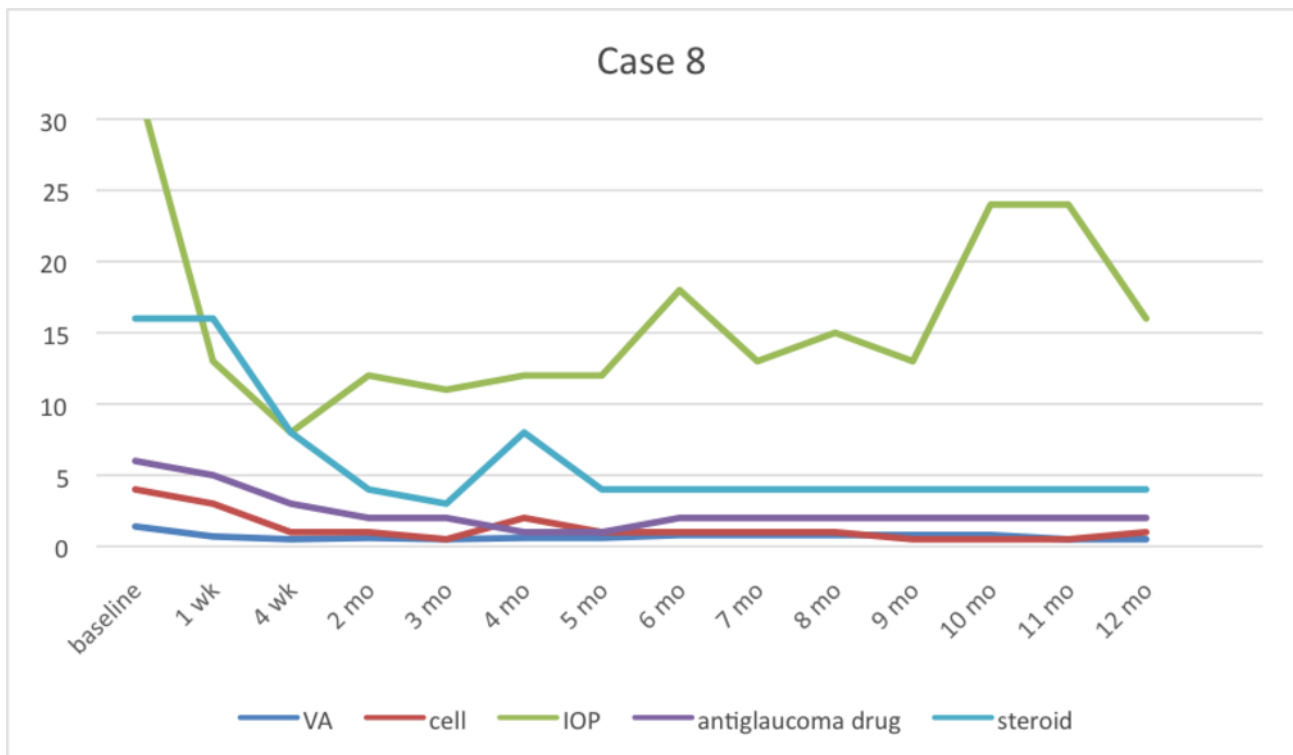


Figure 8 Case 8 had no recurrence; however he was still on medicine. At 10th month follow-up, the patient had poor compliance to take antiglaucoma medicine. IOP, intraocular pressure; VA, visual acuity.

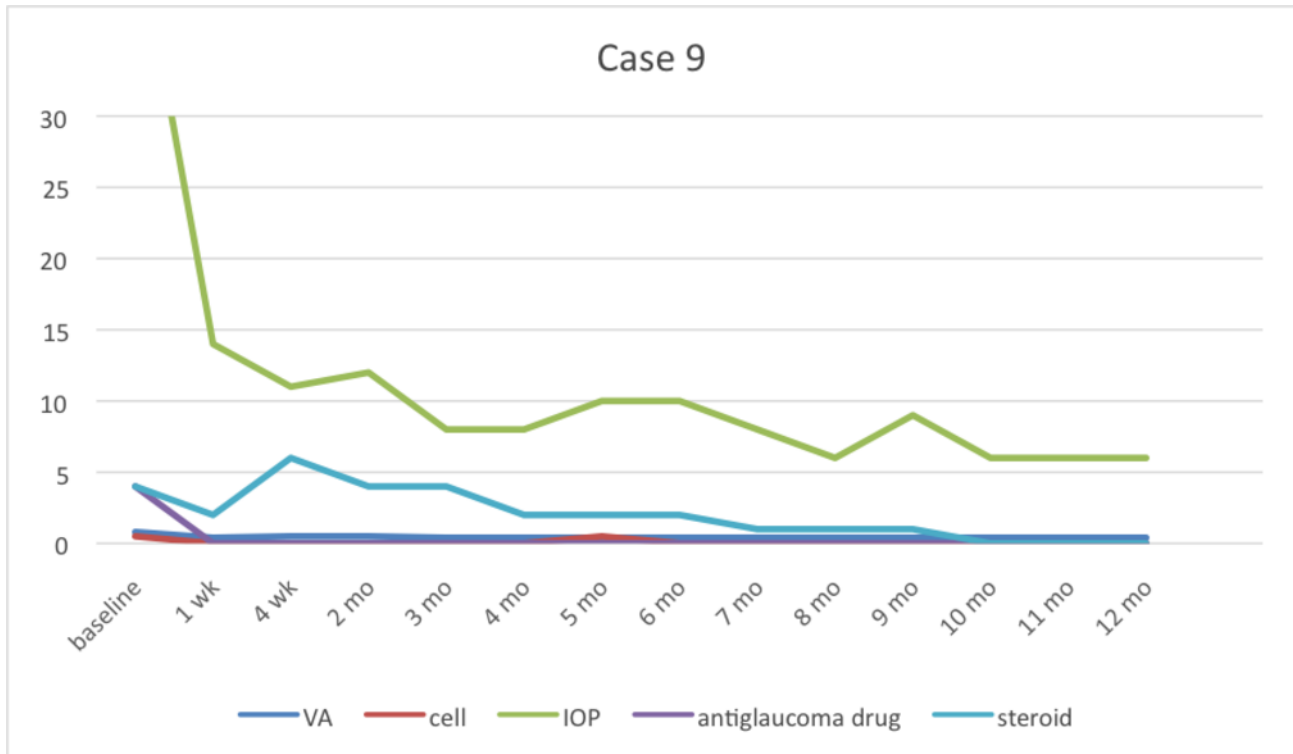


Figure 9 Case 9 could be stopped using 2% topical ganciclovir at 11th month without any recurrent symptoms. IOP, intraocular pressure; VA, visual acuity.

After the patients had used topical 2% ganciclovir for at least 6 months, they completed questionnaires asking about unexpected symptoms including irritation, redness, foreign body sensation, photophobia,

dry eye, blurred vision, abnormal discharge and tearing together with questionnaires asking about characteristics of medication change including change in colour or sedimentation. Side effects from using topical

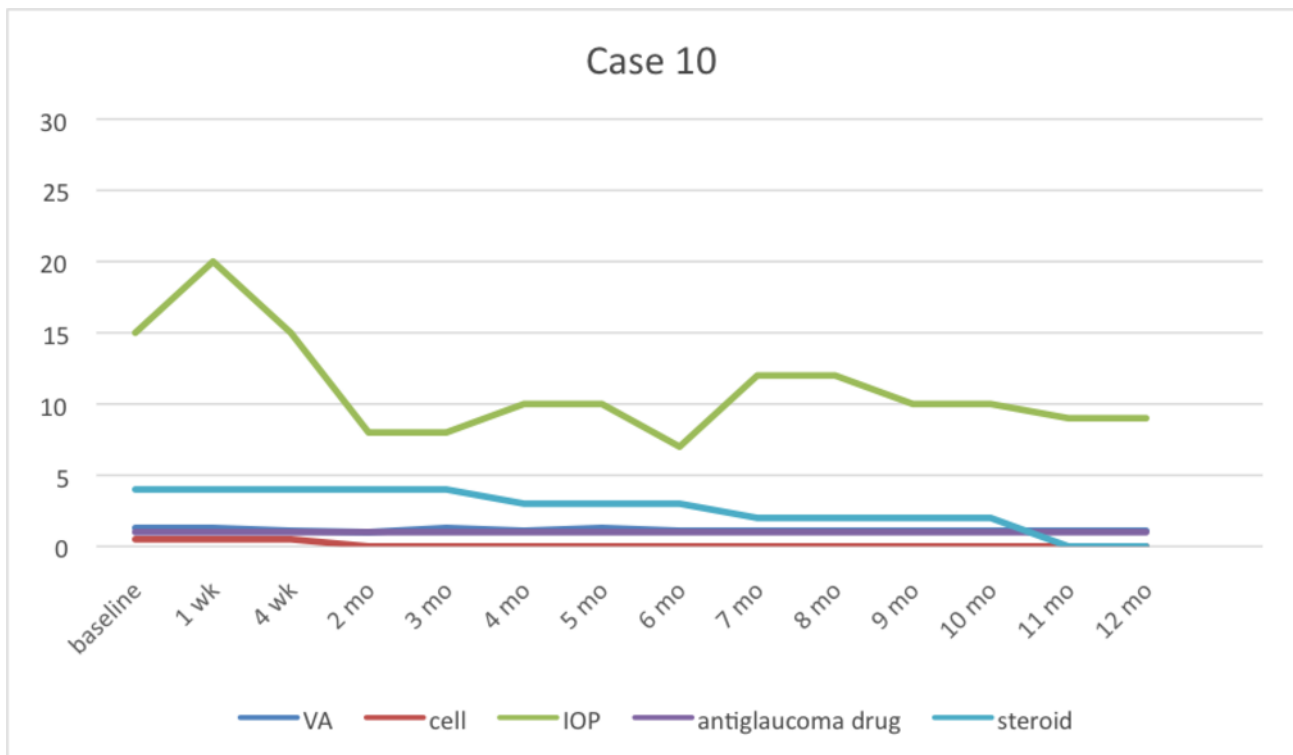


Figure 10 Case 10 could be stopped using 2% topical ganciclovir at 11th month without any recurrent symptoms. IOP, intraocular pressure; VA, visual acuity.

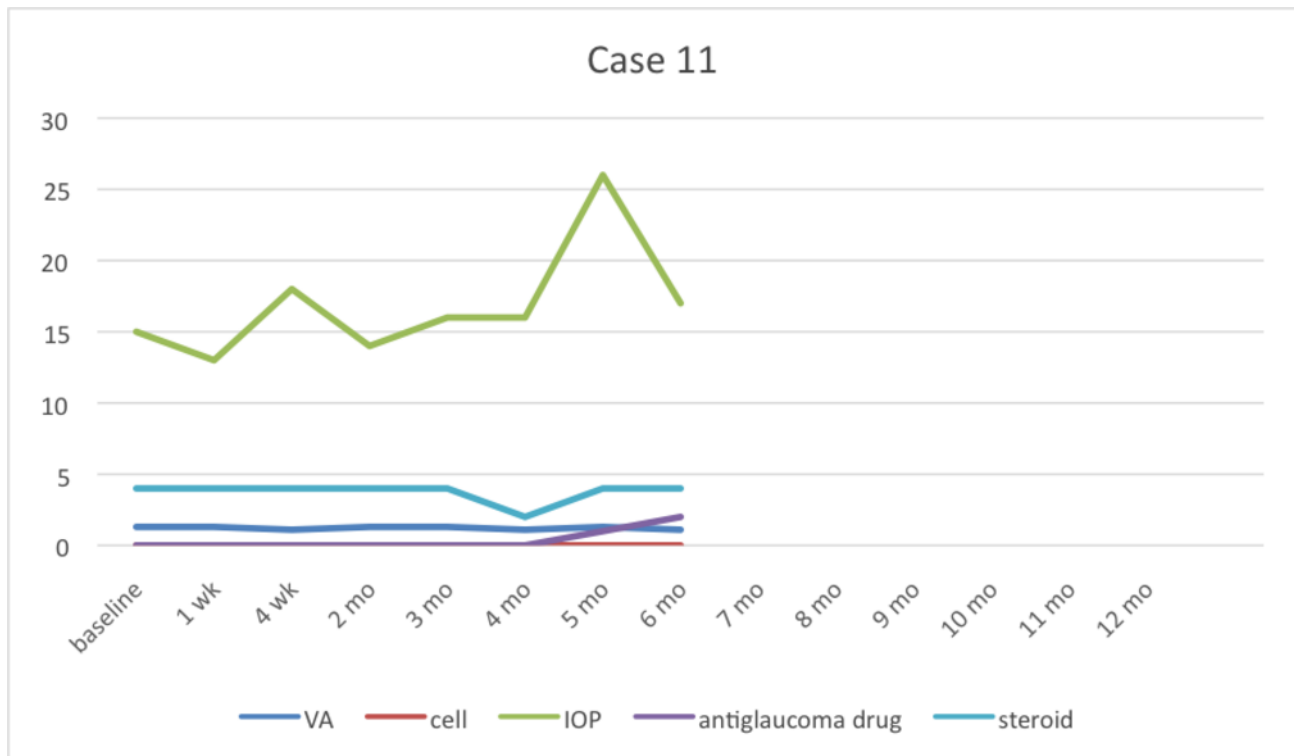


Figure 11 Case 11 stopped taking medicine by herself at 2 weeks then the recurrent symptoms occurred at 5th month. After that topical 2% ganciclovir was restarted. IOP, intraocular pressure; VA, visual acuity.

eye drops including discharge, conjunctival reaction, punctate epithelial erosion and epithelial defect were also recorded every visit.

The primary outcome was to evaluate the efficacy of topical 2% ganciclovir, while the secondary outcome was to evaluate its safety. All data were recorded using the STATA/MP V.12 Program.

Table 6 Factors between recurrent and non-recurrent group

	Non-recurrent Median (min–max)	Recurrent Median (min–max)	p Value
No.	5 (45%)	6 (55%)	0.855*
Age	41.00 (28.00–81.00)	51.00 (29–76)	
Duration (months)	48.00 (1.00–60.00)	59.50 (12–204)	0.313*
Visual acuity	1.20 (0–1.40)	0.20 (0–1.30)	0.195*
Cell	0.50 (0.50–4.00)	0.25 (0–1.00)	0.159*
KPs			0.182†
No	1 (20.00)	–	
Yes	4 (80.00)	6 (100.00)	
IOP	32.00 (15–44)	22.5 (14–40)	0.314*
Antiglaucoma drug	4 (1–6)	3 (0–4)	0.511*
Steroid	4 (2–16)	4 (4–6)	0.672*

*Mann-Whitney U test.

†Fisher's exact test.

Significant (p<0.05).

In case 8, recurrent CMV uveitis was defined as unilateral, high IOP, coin-shaped KPs, localised corneal oedema and normal retina while recurrent in Behcet's disease should be bilateral, low IOP, fine KPs or some retinitis progression.

CMV, cytomegalovirus; IOP, intraocular pressure; KPs, keratic precipitates.

Table 7 Clinical manifestations after using topical 2% ganciclovir treatment

	No		Yes	
	n	%	n	%
Red eye	10	90.91	1	9.09
Foreign body sensation	10	90.91	1	9.09
Eyelid swelling	10	90.91	1	9.09
Photophobia	11	100.00	–	
Dry eye	11	100.00	–	
Blurred vision	10	90.91	1	9.09
Yellowish discharge	11	100.00	–	
Tearing	9	81.82	2	18.18
Irritated eye	8	72.73	3	27.27
Others	11	100.00	–	

Statistical analysis was performed using IBM SPSS statistics, V.23.

This research was approved by the Phramongkutklo Institutional Review Board. Informed consent was obtained from all patients after receiving protocol information.

RESULTS

Clinical responses to topical 2% ganciclovir

Eleven eyes in 11 patients were enrolled in this study. Patient characteristics and demographic data are summarised in tables 1 and 2. The patients comprised eight men and three women, 28–81 years old (49.0 ± 17.8 years). They had the disease before CMV was detected for a mean of 54.0 ± 54.9 months. Two patients underwent penetrating keratoplasty from unknown corneal decompensate; however, they experienced graft rejection and poor visual outcome later. Three of 11 patients (cases 1, 4 and 8) had previously been treated with another route of ganciclovir before quitting because of financial problems.

Table 8 Ocular examination after using topical 2% ganciclovir treatment

	No		Yes	
	n	%	n	%
Discharge	11	100.00	–	
Conjunctival reaction	11	100.00	–	
Punctate epithelial erosion	11	100.00	–	
Epithelial defect	11	100.00	–	

Regarding initial clinical presentations (table 3), the average BCVA was 0.2, ranging from 0 to 1.4. Coin-shaped and stellate KPs were detected in 10 eyes (90.9%); mild anterior chamber inflammation was observed in eight eyes (72.7%), while hypopyon was present in one eye (9%) of case 8 receiving oral 2 mg/kg/day of cyclophosphamide therapy. Fundus examinations were normal in all patients. Topical antiglaucoma medications, acetazolamide tablets and 50% glycerine solution were used in 10 patients (90.9%) with an average of three bottles (0.5% timolol, brimonidine and 1% brinzolamide). However, elevated IOPs were still present in six eyes (55%). All cases were using topical steroids, mostly 1% prednisolone acetate except cases 4 and 10 using loteprednal, but at various frequencies, 2–16 times daily to control inflammation.

Clinical response to topical 2% ganciclovir therapy at 12 months compared with clinical manifestations before starting medication is shown in table 3. All cases showed positive responses to therapy either improved BCVA, decreased anterior chamber cells from 0.5 to 0, eliminated KPs, decreased IOP from 28 to 12 mm Hg, reduced number of antiglaucoma drugs from 3 to 0 bottles and reduced frequency using steroid eye drops from 4 to 0 times daily (tables 4 and 5). Two cases (cases 5 and 9) underwent trabeculectomy with mitomycin C because of uncontrolled IOP and visual field defect progression (18.18%). One case (case 5) discontinued topical 2% ganciclovir at 6 months after the patient decided to choose commercially available 0.15% ganciclovir gel after filtering surgery. One case was lost to follow-up after 6-month visit. At 12 months, 4 of 11 eyes (36%) could discontinue topical 2% ganciclovir, while 5 of 11 eyes (45%) were treated three to four times daily for maintenance therapy. In addition, 6 of 11 eyes (0.55%) used antiglaucoma drugs (0.5% timolol and 1% brinzolamide) long term as well.

After administering topical 2% ganciclovir, IOP and KPs were rapidly controlled in 1 week with significance ($p < 0.013$ and $p < 0.031$) compared with baseline leading to a decrease in antiglaucoma medication and thereafter significantly ($p < 0.024$) as well (table 4). Anterior chamber cells were significantly controlled at 4 weeks ($p < 0.034$) simultaneously as the frequency of steroid eye drops was significantly reduced ($p < 0.017$). BCVA was the last to improve significantly at 5 months ($p < 0.020$).

At 4 weeks of administering topical 2% ganciclovir, IOP and anterior chamber inflammation were significantly controlled compared with baseline every month regularly. The details of each case are shown in figures 1–11.

Six of 11 cases were recurrent: three cases were recurrent when they stopped using topical steroid eye drops but were still using topical 2% ganciclovir three times daily, while three cases were recurrent after stopping topical 2% ganciclovir (27%). They tended to present poorer VA, less anterior chamber cells and

Table 9 Characteristic of medication change

Medications change	No		Yes	
	n	%	n	%
White sediment	9	81.82	2	18.18
Change colour	11	100	–	
Others	11	100	–	

more KPs in the recurrent group; however, no significance was observed in all factors between the recurrent and non-recurrent groups (table 6).

Side effects of topical 2% ganciclovir treatment (tables 7 and 8)

The most common complaint of symptoms was irritated eye (27.27%), lasting 1–2 min after applying eye drops. The second symptom was tearing (18.18%). Other symptoms including red eye, foreign body sensation, eyelid swelling and temporary blurred vision were also recorded (9.09%). No systemic or serious complications were observed in any of the patients.

Regarding medication (table 9), 2 of 11 patients (18.18%) complained about a small amount of white sediment appearing even though the medication was stored in a cool place. It returned to clear after shaking. Any colour change in medication was undetected.

DISCUSSION

Ganciclovir is a synthetic purine nucleoside, an analogue of quanosine²³ and a well-known medication against CMV. Topical forms of ganciclovir have shown effective penetration through the cornea including the aqueous humour^{24 25} and comprise the first treatment option in CMV anterior uveitis and CMV endotheliitis.

Most studies have demonstrated the efficacy of systemic and topical ganciclovir, but not in timeline details. In particular, ours was the first study to evaluate the response of topical ganciclovir in the first week and then monthly. Although our study showed reduced IOP was the first response when using topical 2% ganciclovir, 18.18% of cases required a trabeculectomy with mitomycin C. In addition, Wong *et al* reported 21.2% of cases developed uncontrolled IOP and underwent glaucoma surgery.

Some studies^{18 19} have specified that KPs and anterior chamber inflammation improved after a 4-week administration of topical ganciclovir similar to our study. Tapering off topical steroid eye drops needs to be slow along with anterior chamber inflammation. That is why at 12th month, some patients were still using once to twice daily. However, BCVA did not improve significantly at 12 weeks, while our study showed it improved significantly at 5 months. Hence,

even though other anterior chamber inflammation was controlled, BCVA was the last significant continuous response.

Chee and Jap found that topical ganciclovir had lower recurrence rates than systemic ganciclovir.²⁶ In this study, we found 27% of discontinued medication was recurrent in anterior uveitis, similar to Koizumi *et al* reporting 36% of cases showed recurrence of inflammation and anti-CMV treatment was repeated¹⁴ as well. Wong *et al* reported topical ganciclovir reduced the number of episodes of recurrent anterior uveitis¹⁷ while using and suggested that maintenance therapy may be required to prevent recurrences²⁷ because ganciclovir, a virustatic agent, does not eradicate viruses in the latent phase.

Our study found unexpected symptoms after using topical ganciclovir; however, they were insignificant and improved by adding artificial tears. No studies reported significant side effects such as ocular discomfort or corneal toxicity from topical ganciclovir 0.15%,^{17 18} 0.5¹⁴ or 2%²⁰ as well. White sediment appeared in some bottles. We recommend shaking the medicine while mixing very well because ganciclovir has relatively small-sized molecules with high lipophilicity causing ganciclovir to be poorly soluble in water.²⁵

Limitations in this study included being a relatively small case series and retrospective non-randomised study. Furthermore, the study should compare the efficacy and safety of other concentrations of topical ganciclovir in a randomised control trial requiring longer term follow-up.

CONCLUSION

Topical 2% ganciclovir alone is a safe and effective medicine to control inflammation in CMV anterior uveitis. The first response is reduced IOP and KPs, and then decreased anterior inflammation. Therefore, extemporaneous preparations of topical 2% ganciclovir are non-invasive, economical and convenient for the hospital where commercial topical ganciclovir is unavailable.

Competing interests None declared.

Patient consent Obtained.

Ethics approval The Phramongkutklao Institutional Review Board.

Provenance and peer review Not commissioned; externally peer reviewed.

Open Access This is an Open Access article distributed in accordance with the Creative Commons Attribution Non Commercial (CC BY-NC 4.0) license, which permits others to distribute, remix, adapt, build upon this work non-commercially, and license their derivative works on different terms, provided the original work is properly cited and the use is non-commercial. See: <http://creativecommons.org/licenses/by-nc/4.0/>

© Article author(s) (or their employer(s) unless otherwise stated in the text of the article) 2017. All rights reserved. No commercial use is permitted unless otherwise expressly granted.

Open Access This is an Open Access article distributed in accordance with the Creative Commons Attribution Non Commercial (CC BY-NC 4.0) license,

which permits others to distribute, remix, adapt, build upon this work non-commercially, and license their derivative works on different terms, provided the original work is properly cited and the use is non-commercial. See: <http://creativecommons.org/licenses/by-nc/4.0/>

REFERENCES

- Skuta GL, Cantor LB, Weiss JS. *Basic and clinical science Course 2012-2013: intraocular inflammation and uveitis*. 77. Canada: American Academy of Ophthalmology, 2012.
- Koizumi N, Suzuki T, Uno T, et al. Cytomegalovirus as an etiologic factor in corneal endotheliitis. *Ophthalmology* 2008;115:292–7.
- Laaks D, Smit DP, Harvey J. Polymerase chain reaction to search for Herpes viruses in uveitic and healthy eyes: a South African perspective. *Afr Health Sci* 2015;15:748–54.
- Santos FF, Commodaro AG, Souza AV, et al. Real-time PCR in infectious uveitis as an alternative diagnosis. *Arq Bras Oftalmol* 2011;74:258–61.
- Woo JH, Lim WK, Si H, et al. Characteristics of Cytomegalovirus Uveitis in immunocompetent patients. *Ocul Immunol Inflamm* 2014;10:1–6.
- Choi JA, Kim KS, Jung Y, et al. Cytomegalovirus as a cause of hypertensive anterior uveitis in immunocompetent patients. *J Ophthalmic Inflamm Infect* 2016;6:32.
- Accorinti M, Gilardi M, Pirraglia MP, et al. Erratum to: Cytomegalovirus anterior uveitis: long-term follow-up of immunocompetent patients. *Graefes Arch Clin Exp Ophthalmol* 2014;252:2029.
- Bloch-Michel E, Dussaix E, Cerqueti P, et al. Possible role of cytomegalovirus infection in the etiology of the Posner-Schlossman syndrome. *Int Ophthalmol* 1987;11:95–6.
- Teoh SB, Thean L, Koay E. Cytomegalovirus in aetiology of Posner-Schlossman syndrome: evidence from quantitative polymerase chain reaction. *Eye* 2005;19:1338–40.
- Markomichelakis NN, Canakis C, Zafirakis P, et al. Cytomegalovirus as a cause of anterior uveitis with sectoral iris atrophy. *Ophthalmology* 2002;109:879–82.
- Chee SP, Bacsal K, Jap A, et al. Clinical features of Cytomegalovirus anterior uveitis in immunocompetent patients. *Am J Ophthalmol* 2008;145:834–40.
- Villarreal EC. Current and potential therapies for the treatment of herpes-virus infections. *Prog Drug Res* 2003;60:263–307.
- de Schryver I, Rozenberg F, Cassoux N, et al. Diagnosis and treatment of cytomegalovirus iridocyclitis without retinal necrosis. *Br J Ophthalmol* 2006;90:852–5.
- Koizumi N, Inatomi T, Suzuki T, et al. Clinical features and management of cytomegalovirus corneal endotheliitis: analysis of 106 cases from the Japan corneal endotheliitis study. *Br J Ophthalmol* 2015;99:54–8.
- Crumpacker CS. Ganciclovir. *N Engl J Med* 1996;335:721–9.
- Choi WS, Cho JH, Kim HK, et al. A case of CMV endotheliitis treated with intravitreal ganciclovir injection. *Korean J Ophthalmol* 2013;27:130–2.
- Wong JX, Agrawal R, Wong EP, et al. Efficacy and safety of topical ganciclovir in the management of cytomegalovirus (CMV)-related anterior uveitis. *J Ophthalmic Inflamm Infect* 2016;6:10.
- Koizumi N, Miyazaki D, Inoue T, et al. The effect of topical application of 0.15% ganciclovir gel on Cytomegalovirus corneal endotheliitis. *Br J Ophthalmol* 2016.
- Fan NW, Chung YC, Liu YC, et al. Long-Term Topical Ganciclovir and corticosteroids preserve corneal endothelial function in Cytomegalovirus corneal endotheliitis. *Cornea* 2016;35:596–601.
- Su CC, Wang IJ, Chen WL, et al. Topical ganciclovir treatment in patients with cytomegalovirus endotheliitis receiving penetrating keratoplasty. *Clin Exp Ophthalmol* 2013;41:339–4.
- Su CC, Hu FR, Wang TH, et al. Clinical outcomes in cytomegalovirus-positive Posner-Schlossman syndrome patients treated with topical ganciclovir therapy. *Am J Ophthalmol* 2014;158:1024–31.
- The Standardization of Uveitis Nomenclature (SUN) Working Group. standardization of uveitis nomenclature for reporting clinical data. results of the First International Workshop. *Am J Ophthalmol* 2005;140:509–16.
- Chou TY, Hong BY: ganciclovir ophthalmic gel 0.15% for the treatment of acute herpetic keratitis: background, effectiveness, tolerability, safety, and future applications. *The Clin Risk Manag* 2014;10:665–81.
- Colin J. Ganciclovir ophthalmic gel, 0.15%: a valuable tool for treating ocular herpes. *Clin Ophthalmol* 2007;4:441–53.
- Castela N, Vermerie N, Chast F, et al. Ganciclovir ophthalmic gel in herpes simplex virus rabbit keratitis: intraocular penetration and efficacy. *J Ocul Pharmacol* 1994;10:439–51.
- Chee SP, Jap A. Cytomegalovirus anterior uveitis: outcome of treatment. *Br J Ophthalmol* 2010;94:1648–52.
- Faulds D, Heel RC. Ganciclovir. A review of its antiviral activity, pharmacokinetic properties and therapeutic efficacy in cytomegalovirus infections. *Drugs* 1990;39:597–638.