

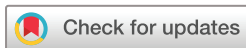# Fungal dysbiosis and decreased tear mucin at the conjunctiva in patients with conjunctival mucosa-associated lymphoid tissue lymphoma

Kazunobu Asao ,<sup>1</sup> Noriyasu Hashida,<sup>1</sup> Daisuke Motooka,<sup>2,3</sup> Teruhisa Tsukamoto,<sup>4</sup> Shota Nakamura,<sup>2,3</sup> Kazuichi Maruyama,<sup>1,3,5</sup> Kohji Nishida<sup>1,3</sup>

**To cite:** Asao K, Hashida N, Motooka D, *et al*. Fungal dysbiosis and decreased tear mucin at the conjunctiva in patients with conjunctival mucosa-associated lymphoid tissue lymphoma. *BMJ Open Ophthalmology* 2023;**8**:e001360. doi:10.1136/bmjophth-2023-001360

► Additional supplemental material is published online only. To view, please visit the journal online (<http://dx.doi.org/10.1136/bmjophth-2023-001360>).

Received 6 June 2023  
Accepted 13 September 2023



© Author(s) (or their employer(s)) 2023. Re-use permitted under CC BY-NC. No commercial re-use. See rights and permissions. Published by BMJ.

For numbered affiliations see end of article.

## Correspondence to

Dr Noriyasu Hashida;  
nhashida@ophthal.med.osaka-u.ac.jp

## ABSTRACT

**Objective** This study aimed to examine the differences in the fungal microbiome between patients with conjunctival mucosa-associated lymphoid tissue (MALT) and healthy controls using metagenomic analysis.

**Methods and analysis** This case-control study was conducted at Osaka University Hospital in Osaka, Japan, from April 2015 to March 2022. Twenty-five consecutive patients with conjunctival MALT lymphoma and 25 healthy volunteers were included. Metagenomic analysis using Internal Transcribed Spacer (ITS)1 deep sequencing and hierarchical clustering was performed to investigate differences in the fungal microbiome. To assess tear environmental change, we measured tear mucin concentrations using ELISA.

**Results** Detailed analyses showed fungal dysbiosis and changes in  $\beta$ -diversity within the conjunctiva of patients with conjunctival MALT lymphoma. Hierarchical clustering revealed that the participants could be divided into three clusters according to the *Malassezia* abundance: cluster I (*Malassezia* abundance above 70%), cluster II (*Malassezia* abundance 25%–70%) and cluster III (*Malassezia* abundance below 25%). Most patients were included in cluster I, whereas most of healthy controls were included in cluster III. The differences were significant. Tear mucin concentrations were significantly lower in patients with MALT compared with healthy controls.

**Conclusion** The metagenomic analysis using ITS1 deep sequencing was useful for identifying the differences in commensal fungi between patients with MALT lymphoma and healthy individuals. The increased prevalence of the *Malassezia* genus and the decreased levels of tear mucin can lead to an allergic response of the conjunctiva, resulting in the pathogenesis associated with conjunctival MALT lymphoma. Therefore, it may be beneficial to initiate treatment when a high abundance *Malassezia* is detected.

## INTRODUCTION

Conjunctival mucosa-associated lymphoid tissue (MALT) lymphoma is a benign proliferative disease involving tumorous development in the ocular conjunctival tissue.<sup>1–4</sup> Previous studies demonstrated that extranodal marginal zone lymphoma is caused by chronic inflammation, and infectious pathogens such

## WHAT IS ALREADY KNOWN ON THIS TOPIC

⇒ In conjunctival mucosa-associated lymphoid tissue (MALT) lymphoma, chronic inflammation at the conjunctiva leads to proliferative tissue. Bacterial infection is suspected to be a contributing factor to the pathogenesis, but the role of fungi is unclear. At the ocular surface, mucins are involved in the maintenance of tissue homeostasis and the elimination of external pathogens that cause inflammation.

## WHAT THIS STUDY ADDS

⇒ Metagenomic analysis and hierarchical clustering revealed fungal dysbiosis and increased prevalence of *Malassezia* in patients with conjunctival MALT lymphoma. At the ocular surface, decreased levels of tear mucin were also detected. Patients with conjunctival MALT lymphoma had a significantly higher frequency of allergic conjunctivitis.

## HOW THIS STUDY MIGHT AFFECT RESEARCH, PRACTICE OR POLICY

⇒ Bacteria are known to be involved in disease development at the ocular surface, but this study suggests that fungal changes are also involved in the development of conjunctival MALT lymphoma. An increased prevalence of *Malassezia* may indicate dysbiosis caused by fungi at the conjunctiva. This information could be useful to determine the best therapeutic intervention option.

as bacteria and viruses are involved in developing conjunctival MALT lymphoma.<sup>1–4</sup> In addition, allergic or chronic conjunctivitis can be observed at the sites of proliferative MALT lesions.<sup>1–4</sup> Additionally, recent studies have reported that dysbiosis of the commensal microbiome in the conjunctiva can occur in patients with conjunctival MALT lymphoma<sup>5</sup>; however, the mechanisms by which the fungal dysbiosis develops have not been thoroughly investigated.

Despite the use of multiple detection methods, it has previously been difficult to comprehensively identify the pathogenic

agents because of culture conditions and primer design.<sup>6</sup> Metagenomic analysis based on 16s and Internal Transcribed Spacer (ITS)1 rRNA sequences could offer comprehensive identification of organisms, including bacteria, fungi and virus; from very small volumes of clinical sample.<sup>7-9</sup> Disease activity at the ocular surface is associated with bacterial dysbiosis.<sup>7-9</sup> Specifically, decreased abundance at the ocular surface microbiota significantly influences the severity of Sjögren syndrome and dry eye.<sup>7-9</sup> In the human body, commensal fungi and their metabolites act as barriers by removing invasive pathogens, helping to stabilise the microenvironment.<sup>7-9</sup> Changes in intestinal fungal metabolism occur if fungal dysbiosis persist for a long period, resulting in the development of pancreatic ductal adenocarcinoma.<sup>7-9</sup> In conjunctival MALT lymphoma, focal disruption of the microbiome and impairments in the mucosal barrier at the conjunctiva may promote tumour development.<sup>5</sup>

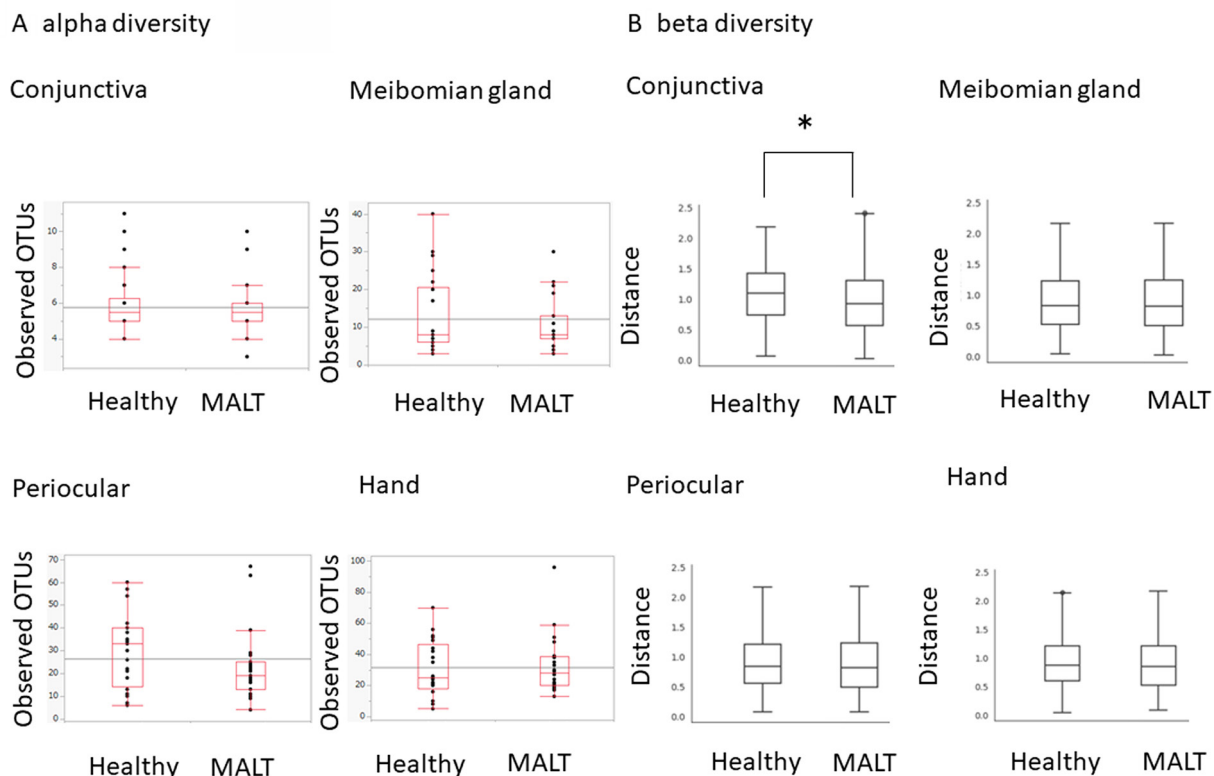
Previous reports have suggested that conjunctival inflammation is associated with dysbiosis and allergies.<sup>5</sup> Similarly, changes in resident bacteria and fungi have been reported in patients with atopic dermatitis.<sup>10</sup> Individuals with allergies in particular should be aware of fungal *Malassezia* spp, which produces a range of immunogenic proteins that can induce the production of specific immunoglobulin E antibodies and maintain the balance of the skin or mucosa.<sup>11-13</sup> These inflammatory changes may also occur in the conjunctiva of the

eye.<sup>11-13</sup> Generally, the mucosal immune system defends the ocular surface against antigenic invasions.<sup>11-13</sup> To maintain mucosal homeostasis, secretory immunoglobulin A (IgA) antibodies are known to protect from invasive bacteria and allergic components, resulting in the prevention of bacterial attachment.<sup>14 15</sup> In addition to IgA secretion, tear mucin and the mucosal barrier interfere with infectious agents and reduce antigen-related damage in the ocular mucosa.<sup>14 15</sup> Bacterial and fungal dysbiosis have been linked to weakening of the immune system in the ocular mucosa, leading to an increase in the likelihood of developing allergic, inflammatory and infectious diseases.<sup>16 17</sup> In addition, this disruption of the immune system has also been associated with the stimulation and growth of tumours.<sup>16 17</sup>

This study aimed to investigate fungal dysbiosis and environmental changes in the tears of patients with conjunctival MALT lymphoma via metagenomic analysis.

## PATIENTS AND METHODS

This case-control study was conducted at Osaka University Hospital in Osaka, Japan, from April 2015 to March 2022. This study included 25 consecutive patients (7 men and 18 women; mean age, 61.7±15.6 years) with biopsy-proven conjunctival MALT lymphoma and 25 age-matched healthy controls (7 men and 18 women; mean age, 58.3±13.0 years). Clinical and background information for each patient is shown in online supplemental



**Figure 1** Fungal  $\alpha$  and  $\beta$  diversity in four body regions. There were no significant differences between healthy controls and patients with conjunctival mucosa-associated lymphoid tissue (MALT) lymphoma in  $\alpha$  diversity for any of the locations (A). A significant difference in  $\beta$  diversity between healthy controls and patients with conjunctival MALT lymphoma was observed at the conjunctiva only (B).

table 1. Exclusion criteria included obvious ocular surface disease without conjunctival MALT lymphoma, history of recent contact lens usage, usage of systemic/topical antibiotics or prescription eye medications during the last 12 months, systemic treatments such as chemotherapy and radiation therapy during the last 12 months, ocular surgery during the last 12 months, active ocular infection, dry eye, systemic diseases such as diabetes or smoking.

Sample collections were performed in a clean ophthalmic treatment room. After instillation of sterile topical proparacaine, DNA swabs (Osaki Sterilized Cotton Swabs S0475-10, Nagoya, Japan) were used to collect samples from the superior and inferior fornixes of the conjunctiva in both eyes. To compare the conjunctiva with other parts of the skin, swabs were also obtained from the hand, meibomian glands and skin around the eyes. Samples were carefully transferred into DNA LoBind tubes (Eppendorf, Fremont, California, USA), and all samples were promptly frozen at  $-80^{\circ}\text{C}$  until DNA extraction.

DNA was extracted from swab samples obtained from the hand, meibomian glands and periocular sites as previously described. Metagenomic analyses were performed via metagenomic analysis using ITS1 deep sequencing at the Research Institute for Microbial Diseases at Osaka University. Each library was prepared following the Illumina standard protocol with a primer set (ITS1-F: CTTGGTCATTTAGAGGAAGTAA and ITS2: GCTGC-GTTCTTCATCGATGC) targeting the ITS1 region of

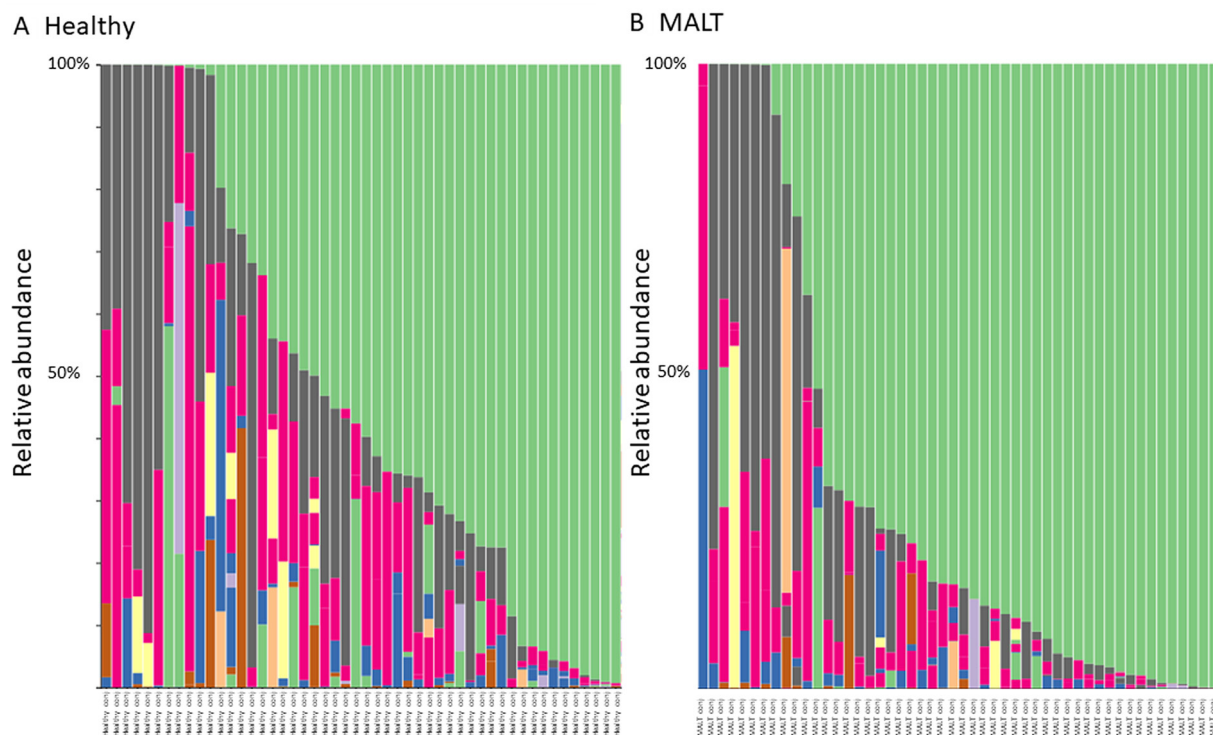
the fungal ribosomal RNA. Then, 301 bp paired-end sequencing of the amplicon was performed using a MiSeq v3 600 cycle kit (Illumina, San Diego, California, USA). Paired-end reads were merged, filtered and denoised using DADA2. Taxonomic assignment was performed using QIIME2 (ver2020.2) in the ntF-ITS1 database.<sup>18</sup>

Schirmer test strips (Ayumi Pharmaceutical Co., Tokyo, Japan) were placed at the outer one-third of the temporal lower conjunctival fornix for 5 min to collect tears. The strips were stored at  $-80^{\circ}\text{C}$  in glass vials until further analysis. Measurement of tear mucin-type O-glycans level was performed using a mucin assay kit (MUC01T; Cosmobio, Tokyo, Japan). ELISA were performed in accordance with the manufacturer's instructions. Mucin levels were quantified using a microplate reader (Infinite 200 PRO; Tecan Japan Co., Tokyo, Japan).

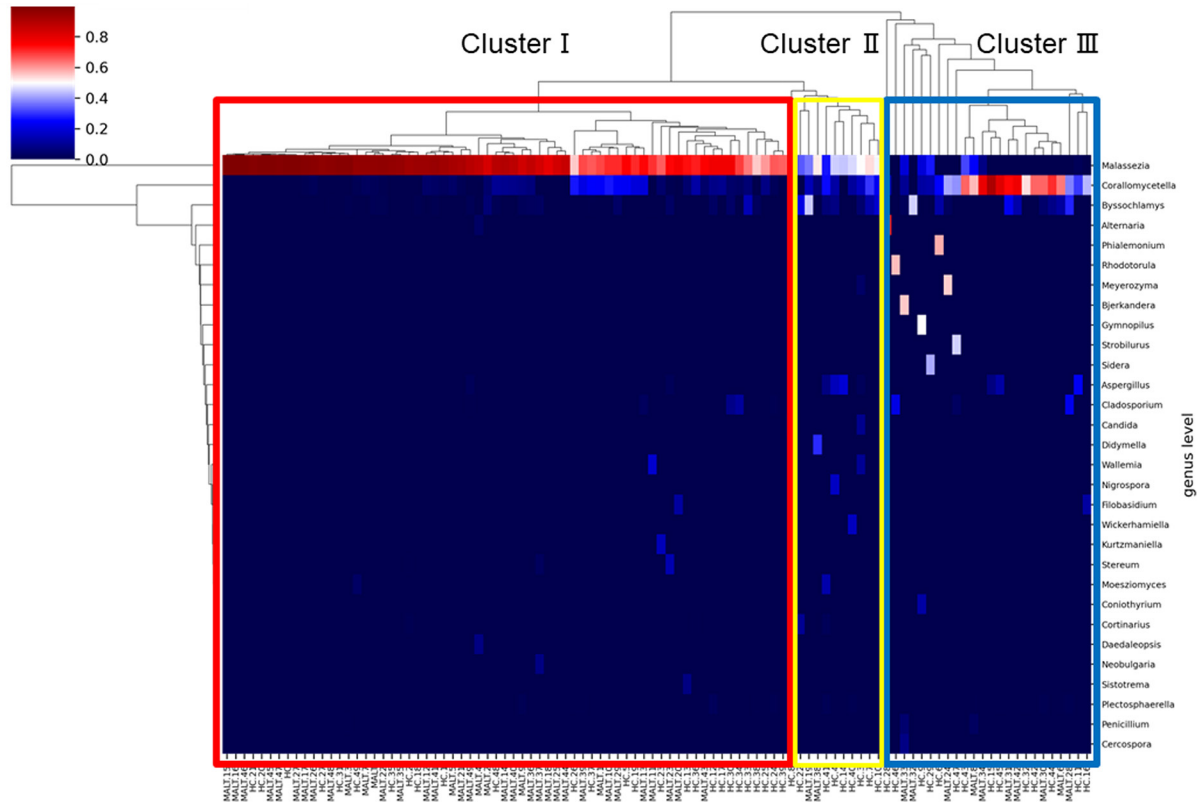
Statistical analyses were performed using JMP software V.17.0 (SAS, Cary, North Carolina, USA). Kruskal-Wallis tests and permutational multivariate analyses of variance were performed to compare  $\alpha$ -diversity and  $\beta$ -diversity, respectively. Microbiota features were compared between groups using the linear discriminant analysis effect size (LEfSe).<sup>19</sup>  $\chi^2$  test and Wilcoxon rank-sum tests were used to identify significant differences at a threshold of  $p < 0.05$ .

#### Patient and public involvement

Patients and/or the public were not involved in the design, or conduct, or reporting, or dissemination plans of this research.



**Figure 2** Composition (bars) and populations (colours) of fungi at the conjunctiva in healthy controls (A) and patients with conjunctival mucosa-associated lymphoid tissue (MALT) lymphoma (B). In both groups, three dominant populations (green: *Malassezia*, black: *Corallomyces*, red: *Byssosclamyces*) were detected. The higher abundance of *Malassezia* was detected in the conjunctival MALT lymphoma group.



**Figure 3** Two-dimensional heat map showing rank-normalised abundances scaled between 0 and 1 for fungal populations in healthy controls and patients with conjunctival mucosa-associated lymphoid tissue (MALT) lymphoma. Populations were classified into three clusters based on the ratio of *Malassezia* abundance. The highest abundance of *Malassezia* was detected in cluster I (red), which included most of patients with conjunctival MALT lymphoma. A moderate abundance of *Malassezia* was found in cluster II (yellow), whereas the lowest abundance was registered in cluster III (blue).

## RESULTS

### Clinical data of patients with conjunctival MALT lymphoma

In the conjunctival MALT lymphoma group, 8 out of 25 patients had allergic conjunctivitis and two had a history of systemic allergy. Among healthy controls, 2 out of 25 had a history of allergic conjunctivitis and 2 had a history of systemic allergy. Patients with conjunctival MALT lymphoma had a significantly higher frequency of allergic conjunctivitis ( $p=0.0343$ ).

### Mycobacterial richness with $\alpha$ diversities and similarities with $\beta$ diversities

Fungal  $\alpha$  diversity among the four body locations in patients with conjunctival MALT lymphoma and healthy controls is shown in figure 1A. The data are presented as mean $\pm$ SE. The number of fungi in the conjunctiva, meibomian gland, periocular skin and hand of healthy controls was 5.88 $\pm$ 1.60, 13.2 $\pm$ 2.42, 29.6 $\pm$ 2.31 and 30.5 $\pm$ 2.27, respectively. The numbers of fungi in the conjunctiva, meibomian gland, periocular skin and hand of patients with conjunctival MALT lymphoma were 5.68 $\pm$ 1.60, 10.8 $\pm$ 2.60, 22.6 $\pm$ 2.36 and 32.6 $\pm$ 2.31, respectively. There were no significant differences in  $\alpha$  diversity in relation to each location (conjunctiva:  $p=0.71$ , meibomian gland:  $p=0.72$ , periocular skin:  $p=0.088$ , hand:  $p=0.77$ ) between

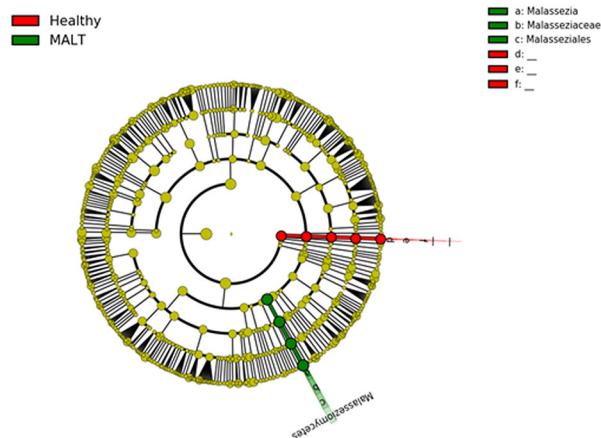
healthy controls and patients with conjunctival MALT lymphoma.

Fungal  $\beta$  diversity among the four body locations in patients with conjunctival MALT lymphoma and healthy controls is shown in figure 1B. A significant difference between healthy controls and patients with conjunctival MALT lymphoma at the conjunctiva was detected ( $p=0.022$ ), with no significant differences at the other three locations (meibomian gland:  $p=0.193$ , periocular skin:  $p=0.063$ , hand:  $p=0.527$ ).

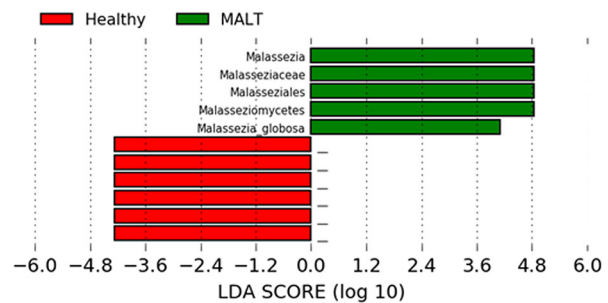
### Fungal composition of the conjunctiva in healthy and MALT lymphoma subjects

The fungal compositions in the conjunctiva of healthy controls and patients with conjunctival MALT lymphoma are shown in figure 2A,B. Each bar represents the fungal composition, and various colour portions represent the abundance of specific species. There were three dominant populations (green: *Malassezia*, black: *Corallomycetella*, red: *Byssoschlamys*). A comparison between patients and healthy controls showed that the abundance of *Malassezia* was significantly higher in the patient group. When the occupancy rate was above 70%, *Malassezia* was found in 35 eyes of the MALT lymphoma group and in 17 eyes of the healthy control group. There were significant

## A result from a linear discriminant analysis effect size program



## B LDA score



**Figure 4** Linear discriminant analysis effect size (LEfSe) programmes showed significant increases (green) or decreases (red) at the conjunctiva. LEfSe analysis revealed a significant increase in the prevalence of *Malassezia* only at the conjunctiva (A). However, the species that were less predominant in patients with conjunctival mucosa-associated lymphoid tissue (MALT) lymphoma could not be identified in the database. Linear discriminant analysis (LDA) scores revealed a significant increase in *Malassezia* abundance (B).

differences between healthy controls and patients with conjunctival MALT lymphoma ( $p=0.00031$ ).

#### Hierarchical clustering and heat-map analysis of healthy and MALT lymphoma subjects

Hierarchical clustering and heat-map analysis identified three clusters of healthy controls and patients with conjunctival MALT lymphomas (figure 3). A predominance of the *Malassezia* genus was found in cluster I (red), which included the majority of patients with conjunctival MALT lymphoma. Those in cluster II (yellow) exhibited a moderate abundance of *Malassezia*, whereas cluster III (blue) included most healthy controls and exhibited the lowest frequency of *Malassezia*.

#### Differences in fungal composition between healthy controls and patients with conjunctival MALT lymphoma according to LEfSe

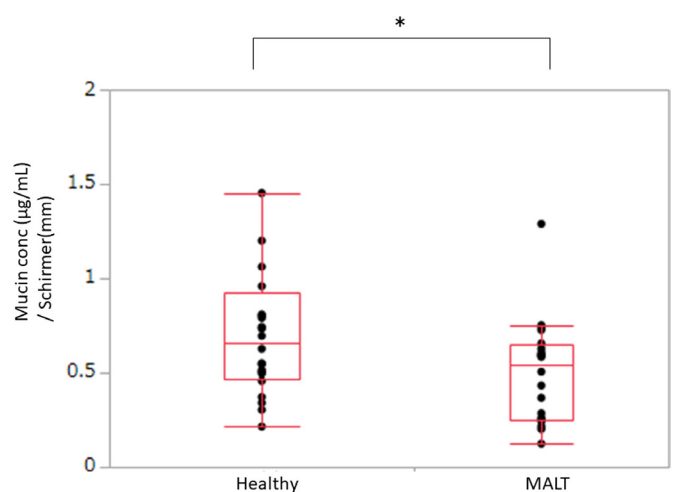
The differences in fungal composition between patients with conjunctival MALT lymphoma and healthy controls at the conjunctiva were analysed using LEfSe. LEfSe showed a significant increase (green) or decrease (red) at the conjunctiva (figure 4A). Linear discriminant analysis scores revealed a significant increase in *Malassezia* abundance (figure 4B), whereas those species with a significantly lower abundance could not be detected in the database.

#### Tear mucin-type O-glycans levels

Tear fluid samples were collected when the inflammation was active. The tear mucin levels of patients with conjunctival MALT lymphoma were  $153.4 \pm 166.9 \mu\text{g/mL}$ , and those of healthy controls were  $252.9 \pm 87.1 \mu\text{g/mL}$  (figure 5). Tear mucin concentrations were significantly lower in patients with MALT compared with healthy controls ( $p=0.0368$ ).

#### DISCUSSION

Our results suggest that metagenomic analysis using ITS1 deep sequencing is useful for detecting fungal microbiomes and fungal dysbiosis in patients with conjunctival MALT lymphoma. As a result, it can be suggested that dysbiosis at the ocular surface and proliferation of a specific fungal genus, *Malassezia*, may be involved in the pathogenesis of MALT lymphoma. In addition, a reduction of mucin was observed at the ocular surface, resulting in the disruption of the mucosal barrier and allergic response. Patients with conjunctival MALT lymphoma



**Figure 5** The levels of tear mucin-type O-glycans in the conjunctiva of healthy controls and patients with conjunctival mucosa-associated lymphoid tissue (MALT) lymphoma were measured. Tear mucin levels were significantly lower in patients with conjunctival MALT lymphoma compared with healthy controls. Wilcoxon rank sum test,  $p<0.0$ .

have a significantly higher frequency of allergic conjunctivitis and fungal dysbiosis at the conjunctiva, which may lead to an allergic response that promotes the pathogenesis of conjunctival MALT lymphoma.

To investigate pathogenic agents, screening tests have previously been performed using a multiplex PCR system.<sup>4</sup> As a result, the presence of human herpes virus, chlamydia, Epstein-Barr virus and bacteria were detected from the samples. However, that of fungal 18S/28S rDNA was not described.<sup>4</sup> In this study, real-time PCR was not performed to detect fungal pathogens because the screening test was not positive. If the amount of fungal DNA had been very small, it would not have been amplified, leading to a negative result. Therefore, we consider that a negative result does not guarantee the absence of fungal DNA. Even if 18S/28S rDNA had been detected, the presence of fungi could have been inferred but the specific fungal species could not have been identified.<sup>9</sup> This is because the primer set can only detect those specific fungal species for which it has been designed.<sup>4,9</sup> The ITS region has a higher degree of variation, and it is possible to identify fungi at the species level.<sup>9</sup> Particularly, compared with 18S rRNA amplicon sequencing, ITS1 sequencing can offer precise information on fungal phylogenies and is suitable for the analysis of fungal diversity.<sup>20</sup>

The richness and diversity of the microbiome serve as defence mechanisms against external exposure.<sup>21,22</sup> In this study, altered  $\beta$  diversity was observed at the conjunctiva but not at other sites. This dysbiosis can result in tumour infiltration caused by the loss of commensal microbiome and changes in the susceptibility to antibiotics.<sup>21,22</sup> Locally, at the conjunctiva, a higher prevalence of *Malassezia* was observed in the patient group compared with the control group. *Malassezia*, which usually exists in the sebum-rich parts of the human skin, is involved in the breakdown of lipids on the body surface, helping to maintain homeostasis.<sup>23,24</sup> Therefore, excessive increases in the population of *Malassezia* can lead to skin barrier dysfunction. Accordingly, *Malassezia* has been implicated as an aggressive factor in patients with atopic dermatitis.<sup>23,24</sup> The commensal *Malassezia* population triggers an immunological response that regulates antifungal immunity, and *Malassezia* fungi can act as allergens when the host immune system is weakened by treatments such as chemotherapy and radiotherapy.<sup>23,24</sup> In this study, patients with conjunctival MALT lymphoma had a higher frequency of allergic conjunctivitis that localised to the ocular surface.

Regarding the dysbiosis involving *Malassezia*, we conclude that it is likely to be a result of conjunctival MALT lymphoma formation. *Malassezia* is present in the body surface as a commensal bacterium.<sup>23,24</sup> Alterations in the microbial composition and a remarkable environmental change at the conjunctiva have been reported in conjunctival MALT lymphoma patients.<sup>5</sup> For example, *Delftia* was significantly more abundant, whereas both *Bacteroides* and *Clostridium* were less abundant at the conjunctiva in patients with MALT lymphoma.<sup>5</sup> The presence of causative bacteria such as *Delftia* could therefore cause environmental disruptions, leading to the onset or progression of conjunctival MALT lymphoma.<sup>5</sup> As a

result, fungal dysbiosis involving *Malassezia* and mucin alterations could have occurred.

Mucins play multiple roles in the protection of mucosal surfaces, and tear mucin-type O-glycans reflect the total amount of mucin.<sup>25</sup> In particular, altered mucin O-glycosylation has been observed with several systemic pathologies, including IgA nephropathy, cystic fibrosis, inflammatory bowel disease and cancer.<sup>26,27</sup> Alterations in mucin-type O-glycosylation were detected at the conjunctival epithelial cells in patients with dry eye. This study revealed a decrease in mucin levels, which might lead to chronic inflammation. In addition to the disruption in the mucin levels, the persistence of allergic conditions leads to inflammation, which may in turn disrupt the function of the mucosal barrier.<sup>28</sup> Decreased tear mucin concentration may allow non-commensal and pathogenic microorganisms to reach the ocular mucosa, leading to infection, inflammation and the proliferation of neoplastic tissue.<sup>29</sup> At the ocular surface, increased *Malassezia* and decreased mucin may contribute to the pathogenesis of dysbiosis. Further studies are needed to clarify whether these changes are responsible for MALT lymphoma.

Hierarchical clustering highlighted the association between *Malassezia* relative abundance and conjunctival MALT lymphoma. Heat map analysis indicated that *Malassezia* was more abundant in cluster I, which included most of the patients with conjunctival MALT lymphoma. The predominance of *Malassezia* may have resulted in decreased diversity of other commensal fungi that are essential to maintain homeostasis, disrupting environmental changes. Cluster II may represent an intermediate stage between health and disease. Therefore, it may be useful to initiate treatment when a high relative abundance of the *Malassezia* genus is observed, and the evolution of its population could be used as a biomarker for the therapeutic effect of treatment. Hence, further studies are required to determine whether fungal dysbiosis plays a role in the development of conjunctival MALT lymphoma.

The limitations of the current study were the low abundance of fungi identified at the ocular surface and the limited number of samples. We could not track changes in the fungal microbiome before and after treatment. In addition, it is difficult to determine whether the dysbiosis and the decrease of tear mucin occurred at the time of initiation or after treatment. A more comprehensive search for associations between fungal dysbiosis and tear mucin changes is needed in the future.

## CONCLUSION

In this study, ITS1 metagenome analysis was successfully employed to identify differences between commensal fungi. Changes in  $\beta$ -diversity were observed within the conjunctiva of patients with conjunctival MALT lymphoma, who also exhibited an increased prevalence of *Malassezia* and decreased levels of tear mucin. These results indicate that alterations in the abundance of the *Malassezia* genus can lead to an allergic response that may be involved in the pathogenesis of conjunctival

MALT lymphoma. Nevertheless, future studies should determine whether interventions targeting dysbiosis, and specifically overabundance of the *Malassezia* genus, can be used for the treatment conjunctival MALT lymphoma.

#### Author affiliations

<sup>1</sup>Department of Ophthalmology, Osaka University Graduate School of Medicine, Suita, Osaka, Japan

<sup>2</sup>Department of Infection Metagenomics, Research Institute for Microbial Diseases, Osaka University, Suita, Osaka, Japan

<sup>3</sup>Integrated Frontier Research for Medical Science Division, Institute for Open and Transdisciplinary Research Initiatives, Osaka University Graduate School of Medicine, Suita, Osaka, Japan

<sup>4</sup>Biology and Translational Research Unit, Department of Medical Innovations, New Drug Research Division, Otsuka Pharmaceutical. Co. Ltd, Naruto, Tokushima, Japan

<sup>5</sup>Department of Vision Informatics, Osaka University Graduate School of Medicine, Suita, Osaka, Japan

**Acknowledgements** This work was supported by Integrated Frontier Research for Medical Science Division, Institute for Open and Transdisciplinary Research Initiatives, Osaka University.

**Contributors** KA, NH and KN planned the experiments. KA, NH and DM performed the research and acquired data. KA, NH and DM analysed the data and wrote the Methods and Results sections of the manuscript. SN and KM supervised the project. KA, NH, TT and KN wrote and edited the manuscript. All authors contributed to the critical revision of the manuscript. NH was responsible for the overall content.

**Funding** This research was supported by the Japan Society for the Promotion of Science (20K18342) (KA) and the Charitable Trust Fund for Ophthalmic Research in Commemoration of Santen Pharmaceutical's Founder (KA).

**Competing interests** None declared.

**Patient and public involvement** Patients and/or the public were not involved in the design, or conduct, or reporting, or dissemination plans of this research.

**Patient consent for publication** Not applicable.

**Ethics approval** The current study adhered to the tenets of the Declaration of Helsinki, the local ethics committee of the Osaka University Medical Hospital approved the study (approval ID 20253), and written informed consent was obtained from all participants. Participants gave informed consent to participate in the study before taking part.

**Provenance and peer review** Not commissioned; externally peer reviewed.

**Data availability statement** No data are available.

**Supplemental material** This content has been supplied by the author(s). It has not been vetted by BMJ Publishing Group Limited (BMJ) and may not have been peer-reviewed. Any opinions or recommendations discussed are solely those of the author(s) and are not endorsed by BMJ. BMJ disclaims all liability and responsibility arising from any reliance placed on the content. Where the content includes any translated material, BMJ does not warrant the accuracy and reliability of the translations (including but not limited to local regulations, clinical guidelines, terminology, drug names and drug dosages), and is not responsible for any error and/or omissions arising from translation and adaptation or otherwise.

**Open access** This is an open access article distributed in accordance with the Creative Commons Attribution Non Commercial (CC BY-NC 4.0) license, which permits others to distribute, remix, adapt, build upon this work non-commercially, and license their derivative works on different terms, provided the original work is properly cited, appropriate credit is given, any changes made indicated, and the use is non-commercial. See: <http://creativecommons.org/licenses/by-nc/4.0/>.

#### ORCID iD

Kazunobu Asao <http://orcid.org/0009-0007-5691-0360>

## REFERENCES

- 1 Wotherspoon AC, Diss TC, Pan LX, *et al*. Primary low-grade B-cell lymphoma of the conjunctiva: a mucosa-associated Lymphoid tissue type lymphoma. *Histopathology* 1993;23:417–24.
- 2 Di Rocco A, Petrucci L, Assanto GM, *et al*. Extranodal marginal zone lymphoma: pathogenesis, diagnosis and treatment. *Cancers (Basel)* 2022;14:1742.
- 3 Lee DH, Sohn HW, Park SH, *et al*. Bilateral conjunctival mucosa-associated lymphoid tissue lymphoma misdiagnosed as allergic conjunctivitis. *Cornea* 2001;20:427–9.
- 4 Usui Y, Rao NA, Takase H, *et al*. Comprehensive polymerase chain reaction assay for detection of pathogenic DNA in lymphoproliferative disorders of the ocular adnexa. *Sci Rep* 2016;6:36621.
- 5 Asao K, Hashida N, Ando S, *et al*. Conjunctival dysbiosis in mucosa-associated lymphoid tissue lymphoma. *Sci Rep* 2019;9:8424.
- 6 An N, Wang C, Dou X, *et al*. Comparison of 16S rDNA amplicon sequencing with the culture method for diagnosing causative pathogens in bacterial corneal infections. *Transl Vis Sci Technol* 2022;11:29.
- 7 Zhang X, M VJ, Qu Y, *et al*. Dry eye management: targeting the ocular surface microenvironment. *Int J Mol Sci* 2017;18:1398.
- 8 Aykut B, Pushalkar S, Chen R, *et al*. The fungal mycobiome promotes pancreatic oncogenesis via activation of MBL activation. *Nature* 2019;574:264–7.
- 9 Limon JJ, Skalski JH, Underhill DM. Commensal fungi in health and disease. *Cell Host Microbe* 2017;22:156–65.
- 10 Hammond M, Gamal A, Mukherjee PK, *et al*. Cutaneous dysbiosis may amplify barrier dysfunction in patients with atopic dermatitis. *Front Microbiol* 2022;13:944365.
- 11 Schmid B, Künstner A, Fährnrich A, *et al*. Dysbiosis of skin microbiota with increased fungal diversity is associated with severity of disease in atopic dermatitis. *J Eur Acad Dermatol Venereol* 2022;36:1811–9.
- 12 Denoyer A, Godefroy D, Célérier I, *et al*. CX3CI1 expression in the conjunctiva is involved in immune cell trafficking during toxic ocular surface inflammation. *Mucosal Immunol* 2012;5:702–11.
- 13 Stern ME, Schaumburg CS, Dana R, *et al*. Autoimmunity at the ocular surface: pathogenesis and regulation. *Mucosal Immunol* 2010;3:425–42.
- 14 Corthésy B. Multi-faceted functions of secretory IgA at mucosal surfaces. *Front Immunol* 2013;4:185.
- 15 Hodges RR, Dartt DA. Tear film mucins: front line defenders of the ocular surface; comparison with airway and gastrointestinal tract mucins. *Exp Eye Res* 2013;117:62–78.
- 16 Xue W, Li JJ, Zou Y, *et al*. Microbiota and ocular diseases. *Front Cell Infect Microbiol* 2021;11:759333.
- 17 Hiam-Galvez KJ, Allen BM, Spitzer MH. Systemic immunity in cancer. *Nat Rev Cancer* 2021;21:345–59.
- 18 Motooka D, Fujimoto K, Tanaka R, *et al*. Fungal ITS1 deep-sequencing strategies to reconstruct the composition of a 26-species community and evaluation of the gut mycobiota of healthy Japanese individuals. *Front Microbiol* 2017;8:238.
- 19 Segata N, Izard J, Waldron L, *et al*. Metagenomic biomarker discovery and explanation. *Genome Biol* 2011;12:R60.
- 20 Yu Y, Yang Q, Petropoulos E, *et al*. ITS3/ITS4 outperforms other ITS region and 18S rRNA gene primer sets for Amplicon sequencing of soil fungi. *Eur J Soil Sci* 2022;73:e13329.
- 21 Zheng D, Liwinski T, Elinav E. Interaction between microbiota and immunity in health and disease. *Cell Res* 2020;30:492–506.
- 22 Richard ML, Sokol H. The gut mycobiota: insights into analysis, environmental interactions and role in gastrointestinal diseases. *Nat Rev Gastroenterol Hepatol* 2019;16:331–45.
- 23 Saunte DML, Gaitanis G, Hay RJ. Malassezia-associated skin diseases, the use of diagnostics and treatment. *Front Cell Infect Microbiol* 2020;10:112.
- 24 Vijaya Chandra SH, Srinivas R, Dawson TL, *et al*. Cutaneous malassezia: commensal, pathogen, or protector. *Front Cell Infect Microbiol* 2020;10:614446.
- 25 Sparber F, De Gregorio C, Steckholzer S, *et al*. The skin commensal yeast malassezia triggers a type 17 response that coordinates anti-fungal immunity and exacerbates skin inflammation. *Cell Host Microbe* 2019;25:389–403.
- 26 Mantelli F, Argüeso P. Functions of ocular surface mucins in health and disease. *Curr Opin Allergy Clin Immunol* 2008;8:477–83.
- 27 Guzman-Aranguez A, Mantelli F, Argüeso P. Mucin-type O-Glycans in tears of normal subjects and patients with non-Sjögren's dry eye. *Invest Ophthalmol Vis Sci* 2009;50:4581–7.
- 28 Brockhausen I. Pathways of O-Glycan biosynthesis in cancer cells. *Biochim Biophys Acta* 1999;1473:67–95.
- 29 Iliiev ID, Leonardi I. Fungal dysbiosis: immunity and interactions at mucosal barriers. *Nat Rev Immunol* 2017;17:635–46.